

First description of an outbreak of cattle intoxication by cyanobacteria (blue-green algae) in the South of Portugal

C. Menezes,¹ MSc; R. Nova,² DVM; M. Vale,³ MSc; J. Azevedo,³ MSc; V. Vasconcelos,^{3,4} PhD; C. Pinto,⁵ DVM, PhD

¹ National Institute of Health Dr. Ricardo Jorge (INSA), Department of Environmental Health, Avenida Padre Cruz, 1649-016 Lisboa, Portugal

² Campo Branco Agriculture Association (A.A.C.B.), Avenida dos Bombeiros Voluntários, 13, 7780-122 Castro Verde, Portugal

³ Interdisciplinary Centre of Marine and Environmental Research (CIIMAR), Terminal de Cruzeiros de Leixões. Av. General Norton de Matos, 4450-208 Matosinhos, Portugal

⁴ Faculty of Sciences, University of Porto, Rua do Campo Alegre, 4069-007 Porto, Portugal

⁵ National Institute for Agrarian and Veterinarian Research (INIAV), Rua dos Lagidos, Lugar da Madalena 4480-655 Vairão, Portugal

Corresponding author: Dr. Carlos Pinto, carlos.pinto@iniav.pt

Abstract

A herd of 53 Angus x Charolais crossbred cows and 1 herd bull grazing a stubble field broke through an electric fence, and gained access to stagnant water from a small river (Ribeira de Oeiras). In less than 19 hours, 20 cows died and 5 were sick with clinical signs of ataxia, recumbence, abdominal distension, opisthotonus, paddling and masticatory movements, frothing at the mouth, and bloody diarrhea. The 5 sick cows later died, and the remaining 29 animals remained healthy. Clinical and pathological findings revealed the presence of hepatic and renal necrosis. In the water samples, several cyanobacterial species were identified, predominantly belonging to the toxic genera *Microcystis*. Altogether, these observations led to a tentative diagnosis of acute hepatotoxicity caused by cyanotoxins. The diagnosis was confirmed by detection of microcystin-LR in the kidney from 1 animal. To our knowledge, this is the first report of microcystin-LR animal poisoning in Portugal.

Key words: cattle, cyanobacteria, intoxication, microcystins, blue-green algae, mortality

Résumé

Un troupeau de 53 vaches Angus x Charolais avec un taureau au pâturage dans un champ de chaume est passé à travers une clôture électrique et a eu accès à de l'eau stagnante d'une petite rivière (Ribeira de Oeiras). En moins de 19 heures, 20 vaches sont mortes et cinq étaient malades avec des signes cliniques incluant l'ataxie, le décubitus, la distension abdominale, l'opisthotonos, le pédalage et des mouvements de mastication, la bouche écumeuse et la

diarrhée sanglante. Les cinq vaches malades sont mortes subséquemment mais les 29 autres animaux sont demeurés en santé. Les constatations cliniques et pathologiques ont révélé la présence de nécrose hépatique et rénale. Dans des échantillons d'eau, plusieurs espèces de cyanobactéries ont été identifiées particulièrement du genre toxique *Microcystis*. Somme toute, les observations suggéraient un diagnostic préliminaire d'hépatotoxicité aiguë associée à des cyanotoxines. Ce diagnostic a été confirmé par la détection de microcystine-LR dans le rein d'un des animaux. À notre connaissance, ceci est le premier cas d'empoisonnement à la microcystine-LR rapporté au Portugal.

Introduction

Cyanobacteria are photosynthetic prokaryotic organisms with vast adaptation to several environments. They are mostly present in aquatic environments where they can form blooms (excessive growth) and scums on surface water under suitable conditions. Blooms are often associated with the production of bioactive compounds including cyanotoxins, resulting in water quality impairment and health hazards, thus posing public health risks.^{3,29} Microcystins are a group of ubiquitous cyanotoxins present in high amounts in cyanobacterial bloom biomass (up to 1% of dry weight),¹ and are the most commonly reported cyanotoxins in Portugal.³⁰ This group comprises more than 246 different structural variants of cyclic heptapeptides,²³ differing in 2 amino acids, and microcystin-LR (MC-LR - with leucine and arginine, respectively) is the most frequently detected worldwide.³ Main routes of exposure to microcystins are the ingestion of contaminated water or food, dermal contact, or inhalation of contaminated water. Toxic effects are observed mainly in

the liver.³ These cyclic heptapeptides exert their hepatotoxicity through protein phosphatase inhibition and may cause haemorrhage and enlargement of the liver to several times its normal size. The acute hepatotoxicity is congener specific; intraperitoneal LD₅₀ in mice ranges from 50 to 1200 µg/kg body weight, with a value of 50 µg/kg body weight for MC-LR.³¹ However, renal and neurotoxic effects have also been reported for some variants.^{4,8,12,14} Concern regarding human cyanotoxin intoxications,¹¹ namely microcystins, resulted in the WHO establishment of a guidance value for drinking water of 1 µg MC-LR/L.

There are worldwide reports of animal intoxications in livestock, with both wild and domestic animals poisoned during cyanobacterial blooms in surface water.³³ However, the number of such descriptions is probably underestimated and in Portugal, to our knowledge, there are no case reports. The increasing characterization and knowledge of these intoxication cases is pivotal for preventing poisonings of pets and livestock, attending its role as indicators of human health risks.

The purpose of the present report is to describe the environmental, clinical, and pathological findings associated with sudden death in 25 cattle caused by acute MC-LR exposure.

Case Details

This paper describes sudden death of 25 cows in a herd of 54 beef cattle (53 cows and 1 bull) near Almodôvar, Alentejo, in the South of Portugal. Cattle were Aberdeen-Angus and Charolais cross, ranging from 1.5 to 4 years of age. They were grazing a stubble field for about 3 weeks, and on August 28, 2017 the animals broke the electric fence that bordered the field and gained access to stagnant water from a small nearby stream (Ribeira de Oeiras). All the animals

were healthy when checked by the herdsman at about 12:00 noon on Sunday, August 27. At that time they were resting under the shade of trees and in bushes surrounding the Oeiras stream, which is normal behavior that time of the year. It is common for cattle to graze in the evening as the temperature declines. On the 28th of August at 7:00 a.m., the herdsman found 20 dead cows scattered across the pasture and 5 sick cows. The other 29 animals did not show any clinical signs during the following weeks after the occurrence. In the same time period, the death of a heron in the Oeiras stream was reported. The Oeiras stream is situated in the South of Portugal, in a region that is characterized by high temperatures, high sunlight incidence, and periods of drought (Figure 1).

The dead animals were in good body condition and hair coats were normal. There was marked abdominal bloating, opisthotonus and soil excavation marks resulting from paddling movements in the terminal phase of the illness (Figure 2). In addition, there was blood-tinged froth and abundant blackened blood from the mouth and nostrils; the facial hair had a yellowish mud-like stain (with a sulphurous color); the eyeballs appeared sunken; and the conjunctiva and the third eyelid presented a violaceous color. There were signs of excessive lacrimation in some of the dead animals. Moreover, the animals exhibited diarrhea with darkened blood in the stools, the rectal mucosa was cyanotic with a mild prolapse, the vaginal mucosa presented a violaceous color, and the skin in the perianal region displayed punctiform hemorrhages (Figure 2). Histopathological examination of the liver revealed scattered multifocal necrosis lesions. There was diffuse tubular necrosis in the kidney, particularly severe in the cortex. Tissues and organs, ruminal content, and water were analyzed for heavy metals, specifically copper, lead, and arsenic. All heavy metal levels were within the normal range, with the exception of 1 kidney sample which had a copper level of 48 mg/kg (reference value <17 mg/kg).²⁵

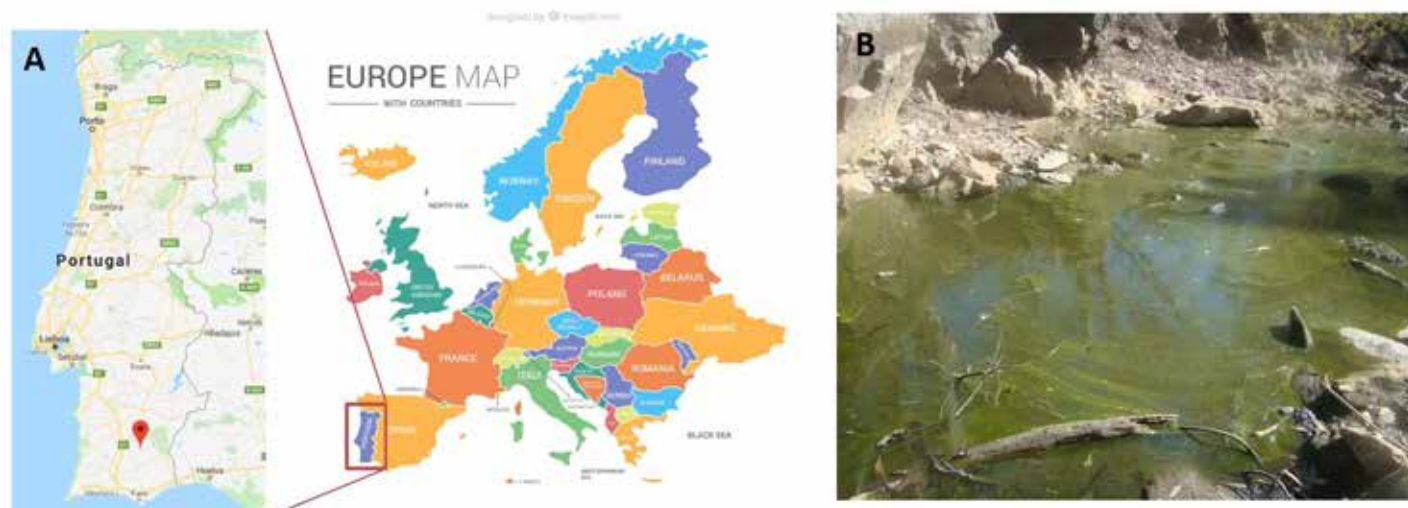


Figure 1. Cattle intoxication with cyanobacteria. A) Geographical localization; B) Oeiras Stream with a cyanobacterial bloom.

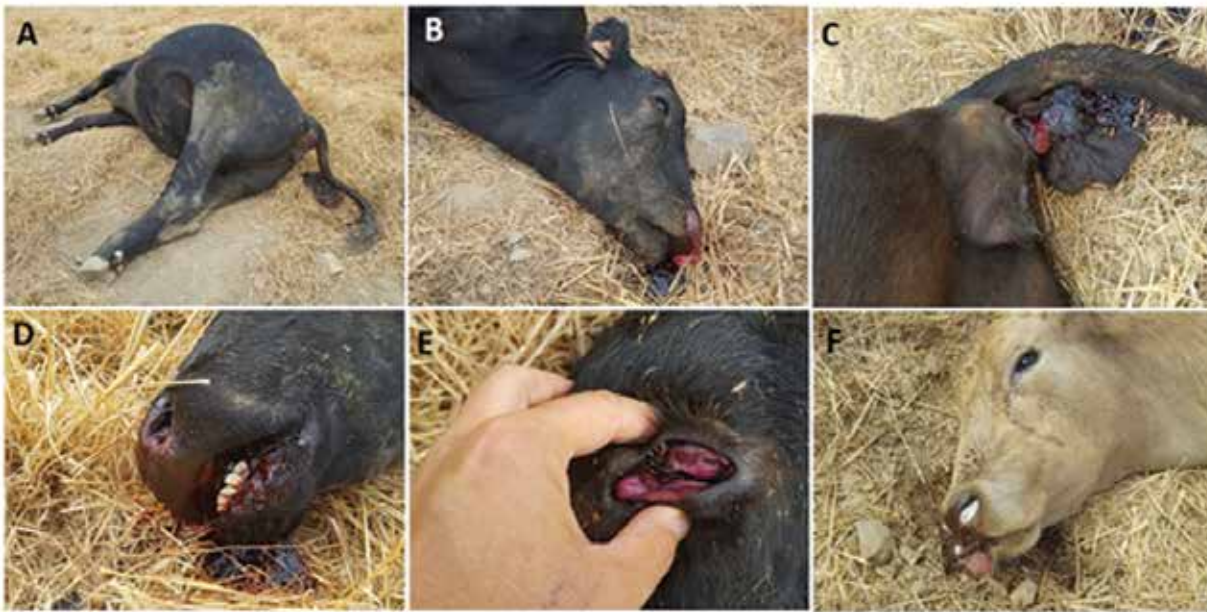

Figure 2. Pathological findings in the intoxicated animals at the outbreak site. A) Abdominal distension, diarrhoea; paddling signs with soil excavation; B) Dorsiflexion of the head and neck (opisthotonus); sunken eye; bloody foam in nostrils; blood in mouth; C) Bloody diarrhea and melena; D) Mouth hemorrhage; E) Third eyelid and conjunctiva mucosa violaceous; F) Foam in nostrils, blood and foam in the mouth and tearing.

Histopathological analysis of the liver revealed a well-preserved parenchyma, with a few foci of scattered hyaline necrosis, some containing numerous long rod bacteria. Necrosis of dispersed hepatic cells and small foci of interlobular infiltration by mononuclear cells (lymphocytes, plasma cells and rare macrophages and neutrophils) was also evident. In the kidney, there was diffuse tubular necrosis, particularly severe in the cortical region, although there were tubes formed by necrotic cells frequently seen in the medullary area of the kidney. Occasionally foci of inflammatory infiltration by mononuclear cells in the interstitial tissue near the renal pelvis was also detected. These lesions were suggestive of dispersed multifocal necrosis triggered by bacterial toxins of intestinal origin, e.g. enterotoxemia. The presence of rod-shaped bacteria in the liver without signs of autolysis suggests intestinal microbial, and the bacteria could have reached the liver through postmortem circulation through the portal vein. Differential diagnosis also included *Clostridium perfringens* type D infection, organophosphate and carbamate pesticide poisoning, nitrate/nitrite poisoning, water deprivation-sodium ion toxicosis, and neurotoxic plants.¹⁸

The liver, kidneys, and feces were analyzed for cyanotoxins by analytical chemistry and immunoassays,¹⁷ specifically microcystins, saxitoxins, and anatoxin-a. The level in the kidney was 0.13 µg microcystin-LR/g. None of the other cyanotoxins were detected in the remaining samples.

The water sample collected after the outbreak (October 24, 2017) presented a diversified phytoplankton community, with predominance of cyanobacteria (70% of total phytoplankton). *Microcystis* was the main genera found (66% of

the cyanobacterial species; Figure 3). Total microcystins were detected at low concentrations (0.16 µg/L).

Discussion

Cyanobacterial blooms are an increasingly frequent phenomena, and it was estimated that 25 to 75% of cyanobacterial blooms are toxic.¹ There are worldwide reports of animal intoxications associated with the occurrence of cyanobacterial blooms in surface waters.²⁴ Francis reported the first documented case of cyanotoxin poisoning in animals in Australia in 1878.¹⁰ Wood reviewed 406 published cases reported from 1800 to 2010, and most cases were in dogs, followed by livestock.³³ Nearly a quarter of the incidents were reported in Europe (23%), and the United States had the highest number of reported cases. An interesting example of animal poisoning by cyanobacteria occurred in Switzerland, where more than 100 cattle deaths were attributed to microcystin poisoning during the last 2 decades.² Microcystins present a constant threat to pastured animals because of their persistence in ponds and streams. Cattle readily drink contaminated water, even consuming algal mats, and poisonings appear to be on the rise.

The number of structural variants frequently present in surface water blooms makes estimating toxicity difficult.²⁷ It is reported that cyanobacteria generally produce in average 4 microcystin congeners,²⁸ but strains that produce up to 47 microcystin congeners have been reported.⁹ In Portugal, although microcystins seem to be the most common toxins,²⁹ there are reports related to saxitoxins,²¹ anatoxin-a,¹⁹ cylin-

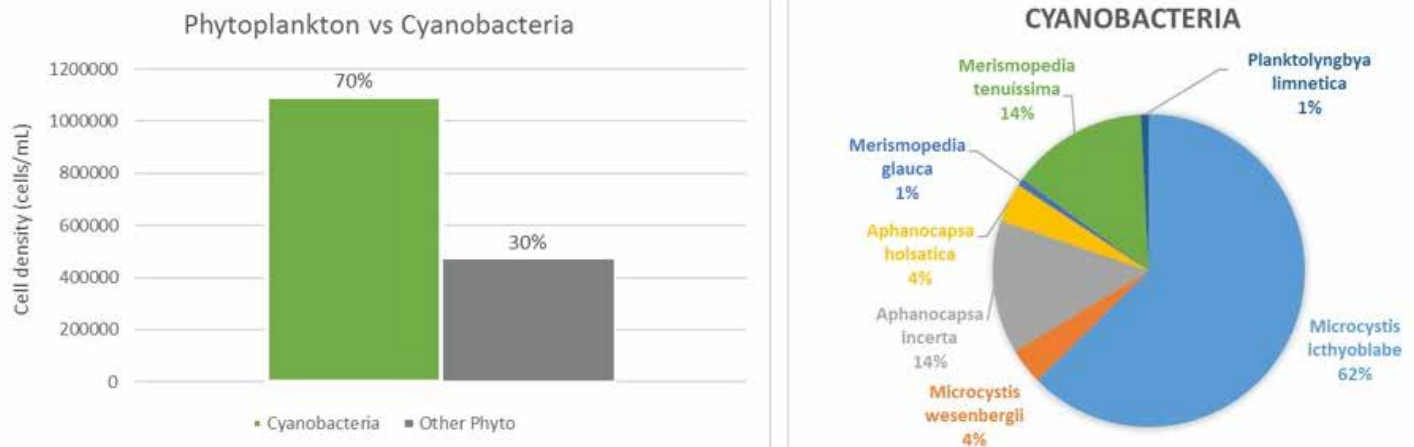


Figure 3. Phytoplankton composition in the water. The graphic on the left shows the relative abundance of cyanobacteria and other groups. On the right is presented the cyanobacterial species composition.

dropermopsin,¹⁶ and BMAA.⁶ This should be considered when monitoring the toxin.

In this case report, the diagnosis of fatal blue-green algae toxicity in 25 cows was based on the characterization of: 1) clinical and pathological findings; 2) exposure to stagnant water from a small river; 3) microscopic identification of toxic cyanobacteria in water; and 4) detection of microcystin-LR in the water and kidney samples. The clinical signs observed in the dead animals were consistent with acute microcystins exposure, such as diarrhea, recumbency, and foam from the mouth.² However, gross observation of the liver did not reveal classical signs of microcystins intoxication, such as hepatomegaly, hemorrhage, and/or necrosis. Although the liver is the primary target organ, toxic effects on the kidney are also reported^{13,14,32} with similar mechanisms of toxicity as in the liver.^{7,15,26} Moreover, the kidneys also excrete microcystins and higher concentrations were found compared to the liver in rats.³² The LD₅₀ dose for microcystins vary from 50 up to 1200 µg/kg (microcystin-LR has a LD₅₀ of 50 µg/kg), compared to 500 µg/kg for strychnine and 10,000 µg/kg for sodium cyanide, 2 known strong poisons.⁵ They also have a steep dose-response curve, and clinical signs of intoxication are generally observed only when an animal is exposed to a near-lethal dose.⁵

The cyanobacterial species found in the Ribeira de Oeiras included *Microcystis ichthyoblabe* and *Microcystis wesenbergii*, both of which produce microcystins.^{20,22} However, the species found in this case are not the most toxic, and the delay in collecting the water sample for analysis may have impaired identification of the cyanobacterial species present at the time of the outbreak. Contrary to other cases, a specific diagnosis was made based on the detection and identification of microcystins in the tissue samples and the persistence of the toxic cyanobacteria in the stream. It is important that sampling include both animal tissues and water the animals were exposed to. This is important to diagnose cyanobacteria intoxications cases in animals.

Acknowledgements

The authors would like to acknowledge Elsa Dias and Miguel Saraiva Lima for the critical reading of the manuscript and helpful suggestions.

Conflicts of Interest

The authors declare no conflicts of interest.

References

- Bláha L, Babica P, Maršálek B. Toxins produced in cyanobacterial water blooms - toxicity and risks. *Interdiscip Toxicol* 2009;2:36-41.
- Briand JF, Jacquet S, Bernard C, Humbert JF. Health hazards for terrestrial vertebrates from toxic cyanobacteria in surface water ecosystems. *Vet Res* 2003;34:361-377.
- Buratti FM, Manganello M, Vichi S, Stefanelli M, Scardala S, Testai E, Furnari E. Cyanotoxins: Producing organisms, occurrence, toxicity, mechanism of action and human health toxicological risk evaluation. *Arch Toxicol* 2017;91:1049-1130.
- Campos A, Vasconcelos VM. Molecular mechanisms of microcystin toxicity in animals. *Int J Molecular Sci* 2010;11:268-287.
- Carmichael W. Cyanobacteria secondary metabolites - the cyanotoxins. *J Appl Bacteriol* 1992;72:445-459.
- Cianca RCC, Baptista MS, Lopes VR, Vasconcelos VM. b-N-methylamino-L-alanine in novel Portuguese cyanobacterial isolates from Minho, Douro and Vouga Rivers. *Amino Acids* 2012;42:2473-2479.
- Dias E, Matos P, Pereira P, Batoréu MCC, Silva MJ, Jordan P. Microcystin-LR activates the ERK1/2 kinases and stimulates the proliferation of the monkey kidney derived cell line Vero-E6. *Tox in Vitro* 2010;24:1689-1695.
- Dias E, Andrade M, Alverca E, Pereira P, Batoréu MC, Jordan P, Silva MJ. Comparative study of the cytotoxic effect of microcystin-LR and purified extracts from *Microcystis aeruginosa* on a kidney cell line. *Toxicol* 2009;53:487-495.
- Fewer DP, Rouhiainen L, Jokela J, Wahlsten M, Laakso K, Wang H, Sivonen K. Recurrent adenylation domain replacement in the microcystin synthetase gene cluster. *BMC Evol Biol* 2007;7:183.
- Francis G. Poisonous Australian lake. *Nature* 1878;18:11-12.
- Giannuzzi L, Sedan D, Echenique R, Andrinolo D. An acute case of intoxication with cyanobacteria and cyanotoxins in recreational water in Salto Grande Dam, Argentina. *Mar Drugs* 2011;9:2164-2175.

12. Hinojosa MG, Gutiérrez-Praena D, Prieto AI, Guzmán-Guillén R, Jos A, Cameán AM. Neurotoxicity induced by microcystins and cylindrospermopsin: A review. *Sci Total Environ* 2019;668:547–565.
13. Menezes C, Alverca E, Dias E, Sam-Bento F, Pereira P. Involvement of endoplasmic reticulum and autophagy in microcystin-LR toxicity in Vero-E6 and HepG2 cell lines. *Toxicol In Vitro* 2013;27:138-48.
14. Menezes C, Valério E, Dias E. The Kidney Vero-E6 Cell Line: A suitable model to study the toxicity of microcystins. In: Gowder S, ed. *New Insights into Toxicity and Drug Testing*. IntechOpen, 2013;29-48.
15. Milutinović A, Živina M, Zorc-Pleskovič R, Sedmak B, Šuput D. Nephrotoxic effects of chronic administration of microcystins -LR and -YR. *Toxicol* 2003;42:281-288.
16. Moreira C, Azevedo J, Mendes R, Vasconcelos V, Antunes A. First report of the occurrence of cylindrospermopsin in Portugal: A new contribution to its continuous global dispersal. *Toxicol* 2017;130:87-90.
17. Moreira C, Ramos V, Azevedo J, Vasconcelos V. Methods to detect cyanobacteria and their toxins in the environment. *Appl Microbiol Biotechnol* 2014;98:8073-8082.
18. Niles GA. Toxicosis of ruminant nervous system. *Vet Clin North Am Food Anim Pract* 2017;33:111-138.
19. Osswald J, Rellan S, Gago A, Vasconcelos VM. Production of anatoxin-a by cyanobacteria strains isolated from Portuguese freshwaters. *Ecotoxicology* 2009;18:1110-1115.
20. Otsuka S, Suda S, Li R, Watanabe M, Oyaizu H, Matsumoto S, Watanabe MM. Phylogenetic relationships between toxic and non-toxic strains of the genus *Microcystis* based on 16S to 23S internal transcribed spacer sequence. *FEMS Microbiol Lett* 1999;172:15-21.
21. Pereira P, Dias E, Franca S, Pereira E, Carolino M, Vasconcelos V. Accumulation and depuration of cyanobacterial paralytic shellfish toxins by the freshwater mussel *Anodonta cygnea*. *Aquat Toxicol* 2004;68:339-350.
22. Sabour B, Loudiki M, Oudra B, Vasconcelos V, Martins R, Oubraim S, Fawzi B. Toxicology of a *Microcystis ichthyoblabe* waterbloom from Lake Oued Mellah (Morocco). *Environ Toxicol* 2002;17:24-31.
23. Spoof L, Catherine A. Appendix 3. Tables of microcystins and nodularins. In: Meriluoto J, Spoof L, Codd GA (eds). *Handbook of cyanobacterial monitoring and cyanotoxin analysis*, 1st ed. John Wiley & Sons, Ltd. 2017;526-537.
24. Stewart I, Seawright AA, Shaw GR. Cyanobacterial poisoning in livestock, wild mammals and birds – an overview. In: Hudnell HK (ed). *Cyanobacterial harmful algal blooms: State of the science and research needs. Advances in experimental medicine and biology*, vol 619. New York, NY: Springer, 2008; 613-637.
25. Suttle NF. The mineral nutrition of livestock, 4th ed. CABI Wallingford, UK, 2010; 290.
26. Valério E, Vasconcelos V, Campos A. New insights on the mode of action of microcystins in animal cells - A review. *Mini Rev Med Chem* 2016;16:1032-1041.
27. Varga A, Puschner B. Retrospective study of cattle poisonings in California: recognition, diagnosis, and treatment. *Vet Med Res Rep* 2012;3:111-127.
28. Vasconcelos VM, Sivonen K, Evans WR, Carmichael WW, Namikoshi M. Isolation and characterization of microcystins (heptapeptide hepatotoxins) from Portuguese strains of *Microcystis aeruginosa* Kutz. emed Elekin. *Arch Hydrobiol* 1995;134:295-305.
29. Vasconcelos VM. Cyanobacteria toxins in Portugal: Effects on aquatic animals and risk for human health. *Braz J Med Biol Res* 1999;32:249-254.
30. Vasconcelos VM, Morais J, Vale M. Microcystins and cyanobacteria trends in a 14 year monitoring of a temperate eutrophic reservoir (Aguieira, Portugal). *J Environ Monit* 2011;13:668-672.
31. Vichi S, Buratti FM, Testai E. Microcystins: Toxicological profile. In: Gopalakrishnakone P, Haddad Jr V, Tubaro A, Kim E, Kem W (eds). *Marine and freshwater toxins*. Toxinology. Springer, Dordrecht, 2016.
32. Wang Q, Xie P, Chen J, Liang G. Distribution of microcystins in various organs (heart, liver, intestine, gonad, brain, kidney and lung) of Wistar rat via intravenous injection. *Toxicol* 2008;52:721-727.
33. Wood R. Acute animal and human poisonings from cyanotoxin exposure — A review of the literature. *Environ Int* 2016;91:276-282.