

# NOVEL MUTATION IN THE MITOCHONDRIAL TRANSFER RNA<sup>Cys</sup> GENE IN A CHILD WITH VOMITING AND MIGRAINE



Almeida LS<sup>1</sup>, Martins E<sup>2</sup>, Santorelli FM<sup>3</sup> and Vilarinho L<sup>1</sup>

<sup>1</sup>Department of Genetics, Research & Development Unit, INSA, Porto, Portugal; <sup>2</sup>Metabolic Diseases Unit, Pediatrics Dept., Porto Hospital Center, Portugal, <sup>3</sup>Molecular Medicine & Neurodegenerative Diseases, IRCCS Fondazione Stella Maris, Pisa, Italy

## Background

Mitochondrial DNA (mtDNA) disorders are an important group of genetic diseases presenting with a multifaceted array of clinical manifestations. Highly energy-dependent tissues such as central nervous system and skeletal and cardiac muscles are commonly involved either as multisystem or as isolated organ disease. Characteristic symptoms include epilepsy, myopathy, deafness and ophthalmoplegia, all associated with point mutations in the mtDNA. Pathogenic mtDNA mutations can be heteroplasmic or homoplasmic. Heteroplasmic mutations are typically associated with mutations in mt-tRNA genes. Mutations in mt-tRNA genes are responsible for the majority of the presentations of a mitochondrial disease being associated with marked clinical heterogeneity. Although tRNA-encoding genes make up only 9% of the entire mitochondrial genome, over 40% of all point mutations reported in the mtDNA are located in tRNA genes. Here, we present a child with vomiting episodes and migraine in whom we found a novel variant in the mitochondrial tRNA<sup>Cys</sup> gene.

## Patient and Methods

### Patient:

We report an 11-year-old female with vomiting episodes and migraine. The patient, a full-term infant, presented with epilepsy in the neonatal period that resolved with valproate treatment (EEG was normal); at 18 months of life she developed paroxysmal torticollis episodes and at the age of 4 years she began with vomiting episodes (mainly during sleep) and migraine. Her psychomotor developmental milestones were within the normal range. Metabolic investigations were normal except for the presence of Krebs cycle metabolites in urinary organic acid profile. The mother is clinically normal. The maternal relatives show clinical alterations, one of her sisters is deaf-mute, the other presents with hypotonia and developmental delay, and the brother (deceased at the age of three months) presented with severe developmental delay and epilepsy. Figure 1 illustrates the family pedigree.

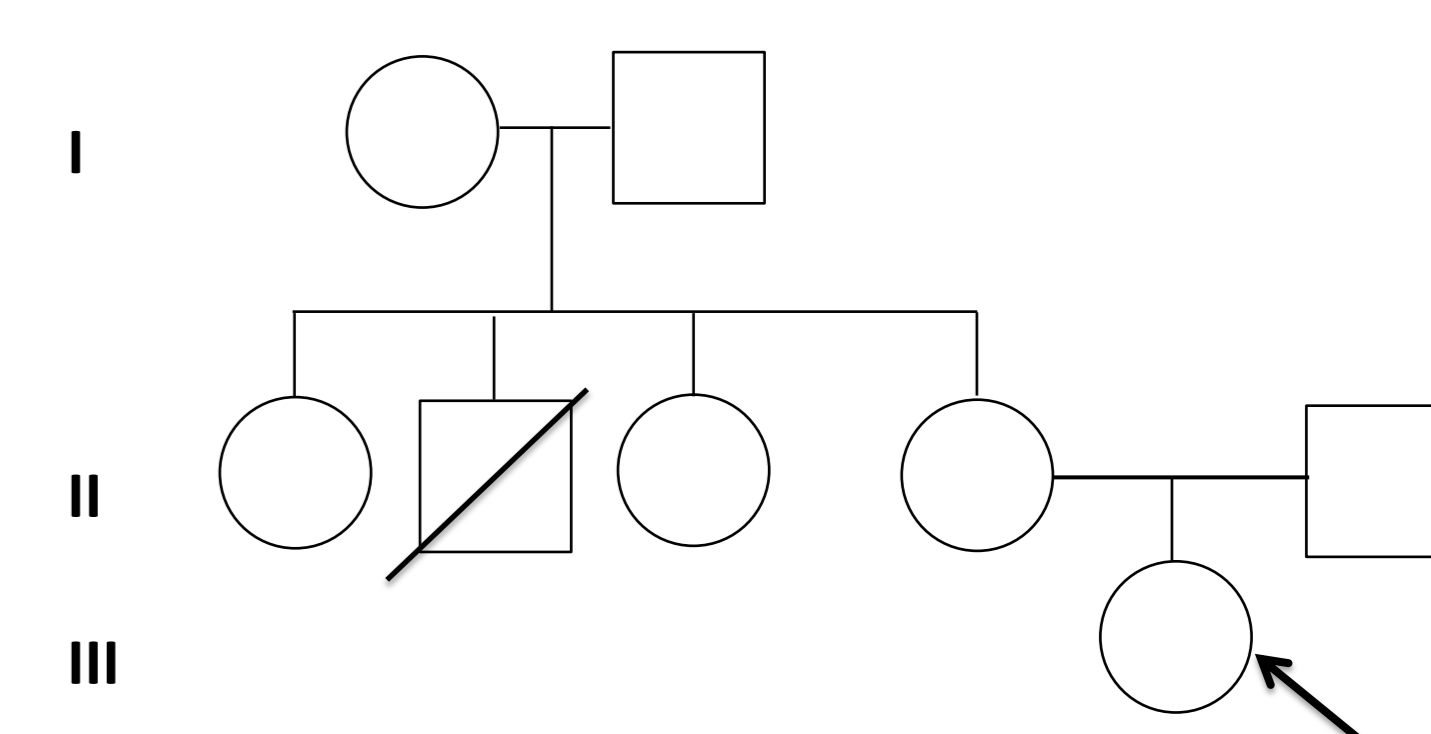


Figure 1. Pedigree of the family

### Methods:

Total genomic DNA was purified from either blood or buccal swab using commercially available kits. The whole mitochondrial DNA (mtDNA) was amplified from blood of the index case and sequenced using a commercially available kit, *mitoSeqr*<sup>TM</sup> Resequencing System for the Human Mitochondrial Genome (Applied Biosystems), according to the procedure recommended by the manufacturer.

## Results

Analysis of the whole mtDNA in the patient revealed the presence of a novel mt-tRNA variant, m.5766C>G in heteroplasmity (Fig. 2A, B). The nucleotide variant is not listed in the mitochondrial databases (MITOMAP, mtDB). The variant was not detectable in the blood and buccal swab DNA from the mother (Fig. 2C, D). Blood from the maternal relatives was still not available for analysis.

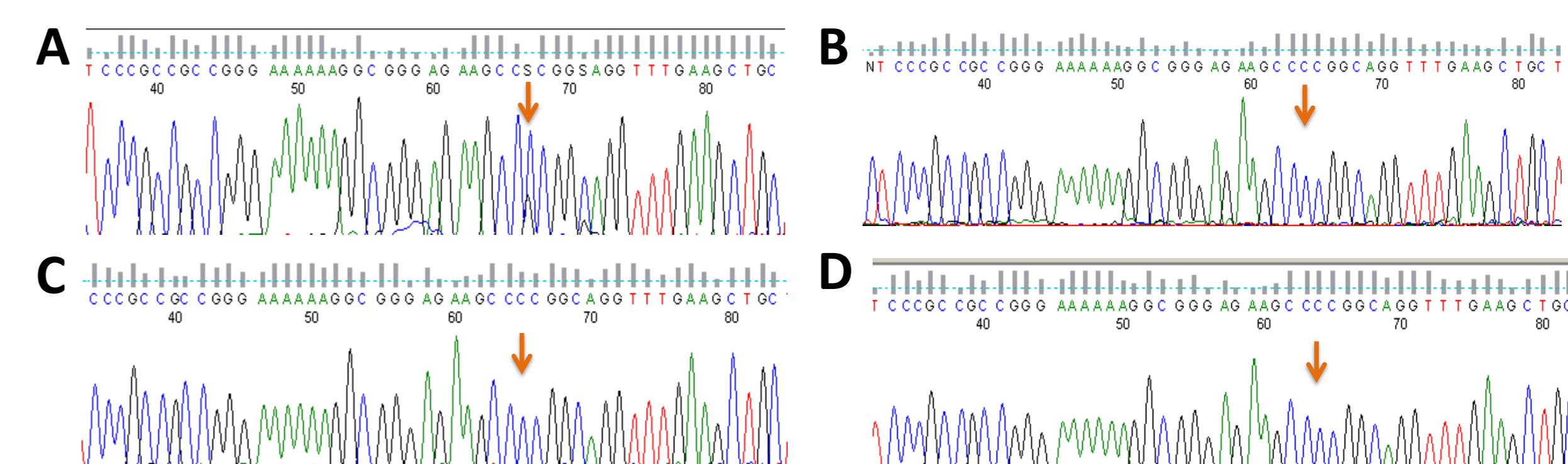


Figure 2. Sequence analysis of mt-tRNA<sup>Cys</sup>. A & B) electropherograms from the index patient from blood and buccal swab DNA, respectively; C & D) electropherograms from the mother of the index patient from blood and buccal swab DNA, respectively.

## Discussion

Analyses *in silico* showed that the m.5766C>G variant, causing the substitution of a C-G base pair to a C-C base pair in the acceptor stem of the tRNA cloverleaf, predicts a loss of free energy of 6 kcal/mol, altering the stability of secondary structure of the molecule.

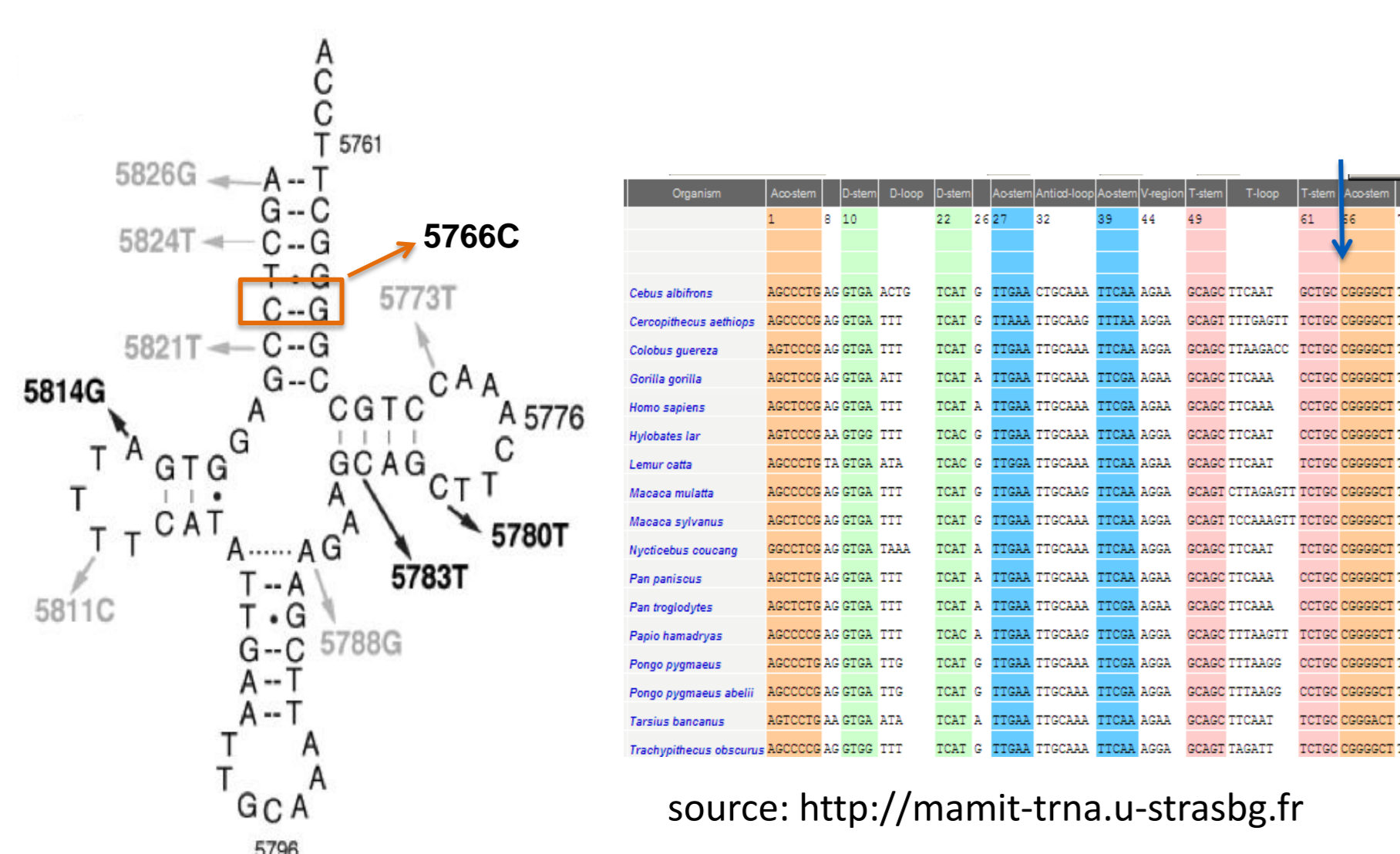


Figure 3. A) Cloverleaf secondary structure of human mitochondrial tRNA<sup>Cys</sup> with pathogenic (black) and polymorphic mutations described; the novel variant is highlighted; B) multiple sequence alignment among 17 primates species illustrating conservation of the tRNA<sup>Cys</sup>

We have detected a novel variant in the mt-tRNA<sup>Cys</sup> (Fig. 3). The detected variant, meets the canonical criteria for pathogenicity: i) the variant, found in blood of the patient, is heteroplasmic; ii) the variant has not been previously reported and was not observed in mitochondrial databases; iii) the affected nucleotide is conserved in the mt-tRNA<sup>Cys</sup> from several species analyzed and iv) *in silico* predictions further support a functional implication of the novel mutation.

In the literature only three pathogenic mutations have been reported in the mt-tRNA<sup>Cys</sup> but associated with *diabetes mellitus*, dilated cardiomyopathy, deafness (m.5783G>A), encephalomyopathy, MELAS, PEO (m.5814T>C), sensorineural hearing loss (m.5780G>A) but none associated with this clinical picture. Our findings broaden the clinical and genetic spectrum of mt-tRNA<sup>Cys</sup> mutations.

### Bibliography:

DiMauro & Schon, 2001, Am J Med Genet 106:18–26; Florentz et al., 2003, Cell Mol Life Sci 60:1356–1375; Yarham et al., 2012, Mitochondrion 12(5): 533–538;

LSA is supported by the Portuguese Foundation for Science and Technology (FCT C2008/INSA/P4).