

CASO CLÍNICO / CLINICAL CASE

Doença de Arranhadela do Gato em mulher de 44 anos de idade

Cat-Scratch disease in a 44-year-old woman

/ N. Murinello¹ / A. Murinello² / H. Damásio²
/ A. Carvalho³ / R. de Sousa⁴

¹ Centro de Saúde de Cascais, Cascais, Portugal

² Serviço de Medicina Interna 1, Hospital de Curry Cabral, Lisboa, Portugal

³ Serviço de Anatomia Patológica, Hospital de Curry Cabral, Lisboa, Portugal

⁴ Centro de Estudos de Vectores e Doenças Infecciosas – Instituto Nacional de Saúde Dr. Ricardo Jorge, Águas de Moura, Portugal

Correspondência:

António Murinello

Av^a Eng^o Ant^o Azev^o Coutinho, Lt 8 r/c dto
2750-644 Cascais
Portugal

Telemóvel: +351 91 8626874

e-mail: amurinello@gmail.com

/ Resumo

A doença da arranhadela do gato é uma zoonose causada pela bactéria *Bartonella henselae*, e transmitida ao homem por inoculação em lesões de arranhadelas ou mordeduras de gatos. Descreve-se aqui um caso de doença da arranhadela do gato numa mulher de 44 anos de idade, imunocompetente, que se apresentou com uma pápula/crosta num dedo da mão direita, linfadenopatias regionais e foi tratada com azitromicina por apresentar uma linfadenopatia epitrocLEAR muito dolorosa. O diagnóstico de infecção por *B. henselae* foi confirmado laboratorialmente por serologia, e PCR (polymerase chain reaction) numa biópsia de gânglio axilar. Foi também detectado DNA de *B. henselae* no sangue do gato da doente, mas não nas quatro pulgas, *Ctenocephalides felis* que parasitavam o gato. Importantes métodos de diagnóstico como a técnica de PCR e sequenciação permitem caracterizar a espécie ou estirpe responsáveis pela infecção no homem uma vez que actualmente existem novas espécies de *Bartonella* emergentes a causar a mesma doença. Para além disso é extremamente importante para a epidemiologia das doenças existentes no nosso país saber quais as espécies que circulam e que podem causar doença no homem.

Palavras-chave: Doença da Arranhadela do Gato, *Bartonella henselae*, Pulga do gato *Ctenocephalides felis*, Azitromicina.

/ Abstract

Cat-Scratch Disease (CSD), a zoonosis caused mainly by Bartonella henselae, is transmitted to humans by inoculation into wounds caused by scratches and cat bites.

We report a case of CSD of an immunocompetent 44-year-old woman, kitten owner, presenting a papule/crust in a finger of the right hand, regional lymphadenopathies, and treated with azithromycin due to distressful and painful epitrocLEAR lymphadenopathy. The diagnosis of B. henselae infection was confirmed by serology and by PCR on lymph node biopsy. It was possible also to detect the presence of Bartonella DNA in the cat's blood but not in the four Ctenocephalides felis fleas collected from the cat. PCR is a useful tool for the characterization of Bartonella

species involved in patient infection since there are other emerging species which can also cause the same disease. In Portugal it is urgent to identify which *Bartonella* species are circulating and are causing disease in humans.

Key-words: Cat-Scratch Disease, *Bartonella henselae*, Azythromycin, *Ctenocephalides felis*.

/ Introduction

Bartonella are aerobic, Gram-negative, fastidious, intracellular bacilli, and at least ten out of twenty *Bartonella* species already described are capable of causing human disease (*B. bacilliformis*, *B. henselae*, *B. quintana*, *B. elizabethae*, *B. clarridgeiae*, *B. grahamii*, *B. vinsonii* subsp. *berkhoffii*, *B. alsatica*, *B. koehlerae*, and *B. rochalimae*)^[1-3].

Cats are reservoirs of several infectious agents and potential sources of infection to humans. The most important *Bartonella* species associated with cats and transmitted to man is *B. henselae*, which causes Cat-Scratch Disease (CSD), and occurs more frequently in children. *B. henselae* is the usual etiologic agent of CSD, although *B. clarridgeiae* has also been associated with the disease. Human isolates of *B. henselae* come from a limited subset of *B. henselae* strains, and are frequently different from those found in cats, suggesting rearrangements under selection pressure in humans^[4]. Two main genogroups of *B. henselae* have been identified in humans and cats: Houston, 16S type-I and Marseille, 16S type II^[1].

B. henselae is transmitted by contaminated flea feces into wounds through scratches with soiled claws or through contaminated saliva of a cat bite (typically a kitten). Kittens are more frequently found with bacteremia, and may therefore be more likely to transmit the disease than adult cats^[5]. Bacteremic cats are usually flea-infested, free-roaming, or from multi-cat living situations^[6]. The main flea vector parasitizing cats is the *Ctenocephalides felis* flea^[1]. The presence of cat fleas is essential for maintenance of the infection within cat populations. Fleas ingest *Bartonella* organisms from bacteremic cats during blood meals and excrete them in feces. It is probable that naïve cats are infected by regurgitation of contaminated saliva during a subsequent blood meal. Contamination of infected fleas into wounds, claws and mouth, many times during cat fighting, as well as ingestion of infected fleas and feces, play a role in cat-to-cat transmission. Notwithstanding, cats are usually non-symptomatic carriers, and only get ill if they are immunosuppressed. The possibility of direct transmission by cat fleas to humans should not be excluded^[7].

Among healthy individuals, CSD usually has a typical self-limiting course of papules/pustules at the inoculation site followed by ipsilateral regional lymphadenopathy, resolving spontaneously over 2-5 months with rare permanent sequelae. In 10% of cases atypical presentations may occur with many clinical expressions. Infected HIV patients have a higher *B. henselae* prevalence and increased susceptibility, and higher rates of undiagnosed and chronic infections as well as more serious and even fatal infections are observed^[8].

The differential diagnosis of typical CSD includes many causes of unilateral lymphadenopathy: typical or atypical mycobacterial diseases, tularemia, plague, brucellosis, syphilis, sporotrichosis, histoplasmosis, toxoplasmosis, infectious mononucleosis, lymphoma, and other neoplasms. In the inguinal area, tender lymphadenopathy in the absence of a genital lesion also suggests *Staphylococcus aureus* infection, and lymphogranuloma venereum^[9].



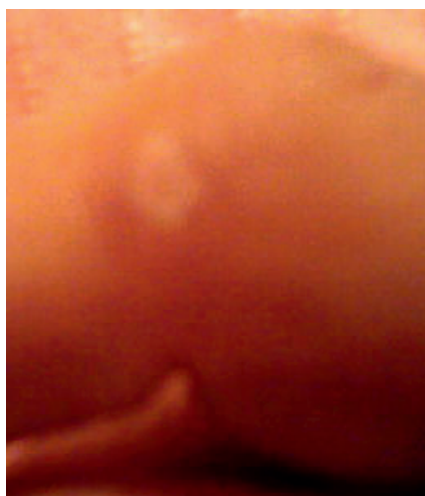

Figure 1 – Inoculation lesion.

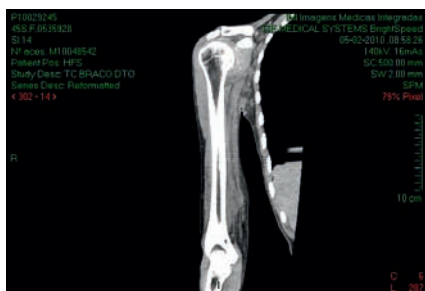


Figure 3 – ICT scan of right arm showing several axilar lymphadenopathies.

The authors present a case of a typical presentation of CSD in an immunocompetent woman, owner of a kitten. For the epidemiological study of the origin of the infection and to provide knowledge to explain an eventual cluster of cases, we additionally performed an investigational study of the patient's kitten and their ectoparasites (fleas).

/ Clinical report

A 44-year-old white Portuguese woman, unemployed, resident in the sea-side small town of Cascais, 25 km west of Lisbon, attending a course in Social Welfare (helping families and the community) sought care at the local public health care Unit in January 13, 2010. The patient complained of a painful swelling on the internal area of the right arm, non-responding to nonsteroidal anti-inflammatory drugs for the last 15 days. She also complained of slightly anorexia, asthenia, easy fatigability, rigors, and a vespertine temperature of 37.2 °C. Both her and her husband shared a history of intravenous drug use for 23 years until 12 years ago. She denied alcohol consumption but referred smoking habits.

Her symptoms started three days after she was scratched by her kitten in the second finger of the right hand. A slightly painful erythematous lesion with a central crust developed at the level of the proximal interphalangeal joint (Fig. 1). One week later a painful lymphadenopathy of about 3 cm diameter appeared 2 cm above the right medial epicondyle, followed by the appearance of other smaller lymphadenopathies localized at brachial and central axillary and subclavian regions (Fig. 2). On physical examination, with the exception of the lymphadenopathies, the patient did not present other relevant findings. Thorax x-ray was normal. Tuberculin reaction was negative. Laboratory evaluation revealed a hemogram of white blood cell count $8.3 \times 10^9/L$: neutrophils $3.826 \times 10^9/L$, lymphocytes $2.764 \times 10^9/L$ - with subpopulations: CD3 86% = $2.377 \times 10^9/L$, CD4 57% = $1.575 \times 10^9/L$, CD8 31% = $0.857 \times 10^9/L$, B 9% = $0.249 \times 10^9/L$, NK 4.5% = $0.124 \times 10^9/L$; ratio CD4/CD8 = 1.83 (1.5-2.5), monocytes $1.377 \times 10^9/L$, hemoglobin 14 g/dL, platelets $2.41 \times 10^9/L$, ESR 22mm/hr; fibrinogen 587 mg/dL (175.0-470), I.N.R. 1.0, APTT 33.6"; IgG 2.123 mg/dL (690-1.400), IgA 213 mg/dL (70-370), IgM 510 mg/dL (40-240). The patient was HCV, HBV, HIV, and VDRL negative. A presumptive diagnosis of cat-scratch disease was made based on epidemiology and the presence of the lymphadenopathies. As the patient complained about the increase of ganglion volume and pain, the treatment was empirically initiated with azithromycin 500 mg daily for five days. Meanwhile, in order to exclude lymphadenopathy suppuration, a CT scan of the right arm was performed.

The CT scan of the right arm revealed several axilar lymphadenopathies (Fig. 3), the most voluminous of which had a diameter of 15 mm, and another localized near the clavicle measuring 16 mm. At the level of the lower third of the arm, with a posterior-internal localization, a more voluminous lymphadenopathy was found, closer to the triceps brachii muscle, surrounded by an intense inflammation that also involved the muscle, the subcutaneous fat, and the superficial aponeurosis. Histochemical slides of the lymph node were also done as previously described. One axilar lymphadenopathy biopsy was fixed in 10 % neutral-buffered formaldehyde, embedded in paraffin, sectioned at 4 µm and stained with hematoxylin and eosin. Microscopic observation revealed a necrotizing stellate granulomatous lymphadenitis (Fig. 4), with rare giant cells, and central microabscesses (Fig. 5). Sections of the biopsy that were stained by different techniques such as PAS, Grocott, Gram, Whartin-Starry and Ziehl-Neelsen did not reveal the presence of any microorganisms. To confirm the diagnosis of *Bartonella* infection a blood sample was collected for serologic tests and lymph node biopsies were performed for molecular studies (PCR detection). Indirect immunofluorescence assay (IFA) with commercial slides from FOCUS Diagnostics (Cypress, CA, USA) detected antibodies reactive to *B. henselae* at a titer of IgG \geq 1024 and IgM=64. PCR amplification was performed on DNA extracted from the patient's lymph node, as previously described, using the primer pair P-bhenfa / P-benr1 for intergenic region

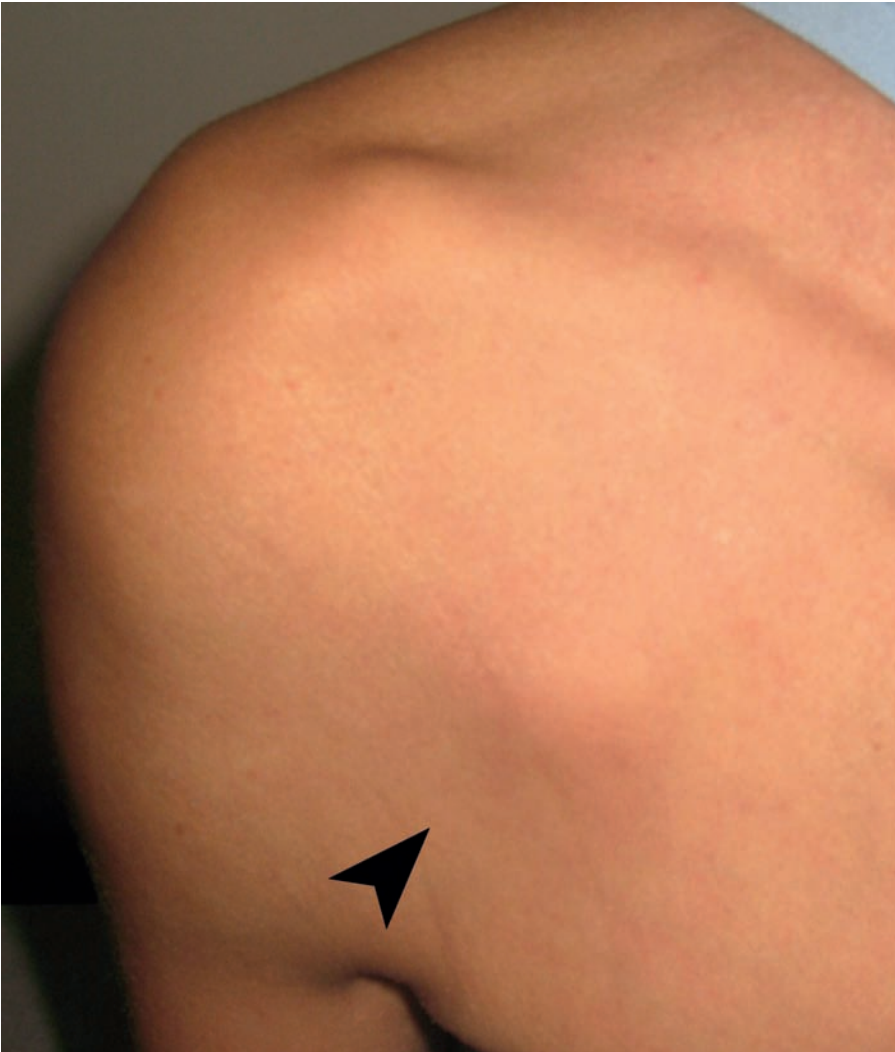

Figure 2 – Ipsilateral subclavian lymphadenopathy.

(ITS) (Rampersad et al, 2005). The amplified fragment was sequenced, showing 100% (187/187bp) identity with the previously reported *B. henselae* URBHLIE9 (GenBank accession no.AF312496), an isolate obtained from a French patient with cat scratch disease. PCR on patient's blood sample was negative.

A week after the treatment, axillary and subclavian lymphadenopathies regressed and the pain disappeared, however epitrochlear lymphadenopathy only resolved after four months. After six months the antibodies titers had decreased, IgM titer was negative and IgG = 256.

In addition to the tests performed on the patient, a blood sample from the kitten was also tested by PCR, and revealed to be positive for *B. henselae*, which confirmed the origin of patient infection to have been through the kitten's scratch. Four fleas collected from the kitten and identified as *Ctenocephalides felis* were also tested by PCR, but no *Bartonella* DNA was detected.

/ Discussion

In this study we described a confirmed clinical case of CSD in a 44 old woman, based on clinical manifestations and the responsible infective species of *B. henselae*. The patient's

kitten showed also to be infected with *Bartonella*. In our report the infection by *B. henselae* was confirmed in our patient but not in her husband, although clustering of cases within families that many times coincided with the acquisition of new pet cats has been reported.

The patient's kitten was acquired in an animal shop where the kittens were living in small cages, in close proximity to each other. Since going to the new owner's house, the kitten had always been indoors, never going outside and never having contact with other animals.

The animal probably acquired the infection previous to coming to the owner's house, where she had had contact with other cats or cat fleas. The kitten although was bacteremic it was asymptomatic as is usual in these animals, and has transmitted the infection to our patient through infected claws. The fleas collected from the cat did not show to be infected with *Bartonella* and we suppose that they did not have time to get infected from the cat while feeding on him or the regular PCR could not detect the *Bartonella* DNA due to sensibility reasons.

In general CSD has an incubation period varying between 3 and 15 days, sometimes longer, and usually presents as a self-limiting disease characterized by erythematous, tender papules or pustules at inoculation site, painful regional ipsilateral lymphadenopathy (which develops in 1 to 7 weeks) of a single or several nodes in the same region (mainly head, neck or upper extremity) or involvement of nodes in multiple regional sites. One third to 60% of patients can have low-grade fever, and less frequently sore throat, malaise, anorexia, nausea, fatigue and headache. Up to one sixth of patients develop lymph node suppuration^[9]. However, the infection is frequently subclinical and few patients ever experience symptoms, suggesting that only a minority of exposures to *B. henselae* result in CSD. Immunocompromised patients such as HIV-infected patients, oncologic patients and transplant recipients, may experience a dramatic and

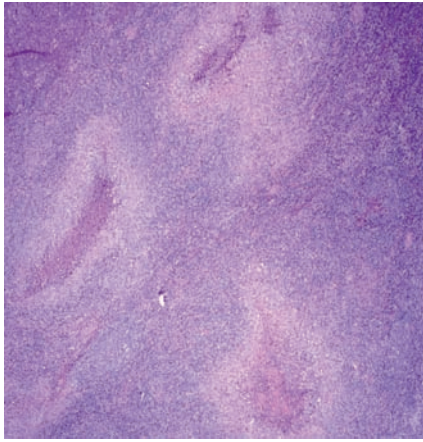


Figure 4 – H&E, 50x - Lymph node histology: multiple stellate necrotizing granulomas.

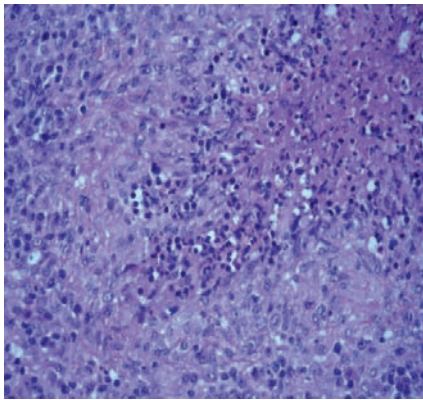


Figure 5 – H&E, 400x - Central microabscess with necrosis, neutrophils, and peripheral palisade of epithelioid cells.

potentially life-threatening course of the disease, with bacteraemia and angioproliferative lesions of the skin (cutaneous bacillary angiomatosis) liver and spleen (bacillary peliosis)^[10].

With the improvement of diagnostic techniques, the known spectrum of the typical clinical disease caused by *B. henselae* (90% of cases overall) has expanded to include rare atypical manifestations such as: (1) prolonged low-grade fever of unknown origin^[11]; (2) transient truncal maculopapular rash; (3) abdominal pain due to an usually self-limited granulomatous hepatosplenic disease or to intraabdominal lymphadenopathy and inflammatory bowel disease; (4) splenic abscesses, with risk of splenic rupture; (5) acute encephalitis; (6) transverse myelitis; (7) ocular disease (neuroretinitis with vision loss; Parinaud syndrome characterized granulomatous conjunctivitis and ipsilateral preauricular lymphadenitis, sometimes affecting the submandibular or cervical lymph nodes; panuveitis; subretinal masses in HIV patients); joint pain (arthritis; synovitis); (9) osteomyelitis; (10) atypical pneumonitis; (11) hemolytic anemia and thrombocytopenic purpura; (12) dermatologic manifestations (maculopapular and urticarial eruptions; pruritic rash; granuloma annulare; erythema nodosum; erythema marginatum; leukocytoclastic vasculitis); (13) subacute infective endocarditis; (14) glomerulonephritis; (15) pseudomalignancy^[12].

The response to infection in immunocompetent patients is: (a) the primary cutaneous lesion consists of a red papule at site of inoculation, which becomes pustular or crusted, observed using microscopy as a circumscribed focus of necrosis, surrounded by histiocytes, often accompanied by multinucleated giant cells, lymphocytes, and eosinophils; (b) a granulomatous and suppurative lymphadenopathy (with central areas of necrosis and multinucleated giant cells, and later on formation of stellate microabscesses), compared with a vasoproliferative (angiogenic) response in immunocompromised patients due to secretion of vascular endothelial growth factor^[12]. However, these histopathological features are consistent, but not pathognomonic for CSD.

In infected patients, the organisms are usually found in vessel walls, in macrophages lining the sinus of lymph nodes, in nodal germinal centers, in non-necrotic areas of inflammation, and in areas of expanding and suppurating necrosis. Electron microscopy of lymph nodes in CSD shows bacilli in clumps in the vascular endothelium, intracellularly and free in necrotic debris^[13].

According to Margileth AM^[14] the diagnostic criteria for *B. henselae* infection should include three of four of the following data: (1) Cat or flea contact regardless of presence of inoculation site; (2) negative serology for other causes of adenopathy, sterile pus aspirated from a node, a positive PCR assay, and/or liver/spleen lesions seen on CT scan; (3) positive ELISA or IFA assay with a titer of IgG > 64; (4) Biopsy showing granulomatous inflammation consistent with CSD or a positive Warthin-Starry silver stain.

Usual laboratory tests in CSD are often nonspecific: normal or mild leukocytosis, normal; elevated, or diminished platelet counts; normal or mildly elevated ESR and fibrinogen; normal liver enzymes; normal results of CSF examination. A rare occurrence is hypercalcemia due to endogenous overproduction of active vitamin D associated with granuloma formation. The majority of Bartonellosis laboratory diagnosis performed is based on serology. However, serologic diagnosis does not lead to the identification of *Bartonella* species due to cross-reactivity^[11]. Cultural examination is difficult and usually unsuccessful. Histopathological examination of affected lymph nodes has the inconvenience of its invasive nature, but can be useful if typical aspects are found and the *B. henselae* is identified by Warthin-Starry silver impregnation stain^[9]. More recently PCR is increasingly being used to identify the *Bartonella* species in different kinds of samples, through different approaches using amplification of different genes. Specificity is excellent (100%), however sensibility ranges from 43% to 76%^[11]. PCR study is essential for clinical investigation, along with epidemiologic data involving the study of reservoirs and vectors of the infectious agent.

The management of typical CSD is primarily symptomatic, as the disease spontaneously resolves in 2-4 months: (a) antipyretics and analgesics are given as needed; (b) application of local heat to the involved lymph nodes; (c) incision and drainage are avoided, because it can result in scars and draining fistula; (d) aspiration of tender, fluctuant nodes may relieve occasional intense pain; (e) antibiotics are not indicated in most cases, but they may be indicated for severe or systemic disease. Faster reduction of lymph node size has been shown using a 5-day course of azithromycin (10 mg/kg on day 1 and 5 mg/kg per day on days 2 to 5), and may be utilized in patients with severe, painful lymphadenopathy^[15]. Other sometimes useful antibiotics are rifampin, doxycycline, ciprofloxacin, or trimethoprim-sulfamethoxazole. All these antibiotics are bacteriostatic and difficultly reach intracellular *Bartonella*. Only aminoglycosides have demonstrated "in vitro" bactericidal activity against *Bartonella*^[11].

The current knowledge of the treatment of atypical and complicated forms of CSD, either in immunocompetent or immunosuppressed patients, is not well stated but it is interesting that the response to antibiotics is usually more dramatic in immunocompromised patients than in those with an intact immune system^[12]. In atypical cases, molecular diagnosis that permit the identification of infective *Bartonella* species/strains are important for further evaluation of the responses to the antibiotics used in patients treatment. In our study the patient responded very well to the azithromycin therapy. However, it is not possible to compare with other Portuguese cases because of the scarce published data. To our knowledge, with an exception of one article, the described Portuguese clinical cases were based in serological tests and only *B. henselae* and *B. quintana* have been associated to cause disease in Portugal^[16-18]. To better understand the epidemiology and clinical spectrum of Bartonellosis in our country, future studies need to be performed in patients and also in different animal reservoirs to identify circulating *Bartonella* species in our country.

/ References

1. Dillon B, Valenzuela J, Don R, Blanckenberg D, Wigney DJ, Malik R, et al. Limited diversity among human isolates of *Bartonella henselae*. *J Clin Microbiol* 2002; 40: 4691-4699.
2. Raoult D, Roblot F, Rolain JM, Besnier JM, Loulergue J, Bastides F, Choutet P. First isolation of *Bartonella alsatica* from a valve of a patient with endocarditis. *J Clin Microbiol* 2006; 44:278-279.
3. Avidor B, Graidy M, Efrat G, Leibowitz C, Shapira G, Schattner A, Zimhony O, Giladi M. *Bartonella koehlerae*, a new cat-associated agent of culture-negative human endocarditis. *J Clin Microbiol* 2004; 42:3462-3468.
4. Zeaiter Z, Fournier PE, Raoult D. Genomic variation of *Bartonella henselae* strains detected in lymph nodes of patients with Cat-Scratch Disease. *J Clin Microbiol* 2002; 40: 1023-1030.
5. Chomel BB, Boulois HJ, Maruyama S, et al. *Bartonella spp* in pets and effect on human health. *Emerg Infect Dis* 2006; 12: 389-394.
6. Carithers HA. Cat-Scratch disease: an overview based on a study of 1200 patients. *Am J Dis Child* 1985; 139: 1124-1133.
7. Alves AS, Milhano N, Santos-Silva M, Santos AS, Vilhena M, de Sousa R. Evidence of *Bartonella spp*, *Rickettsia spp* and *Anaplasma phagocytophilum* in domestic, shelter and stray cat blood and fleas, Portugal. *Clinical Microbiol Infection* 2009; vol 15, suppl 1: 1-3.
8. Pons I, Sanfeliu I, Noguera MM, et al. Seroprevalence of *Bartonella spp* infection in HIV patients in Catalonia, Spain. *BMC Infect Dis* 2008; 8: 58-63.
9. Slater NL, Welch DF. *Bartonella*, including Cat-Scratch Disease. In Mandell GL, Bennet JE, Dolin R. eds. *Mandell, Douglas, and Bennett's Principles and Practice of Infectious Diseases* (6thed) Philadelphia: Elsevier Churchill Livingstone. 2005: 2733-2748.
10. Koton CN. Zoonosis in solid organ and hematopoietic stem cell transplant recipients. *Clin Infect Dis* 2007; 44: 857-866.
11. Malatack JJ, Jaffe R. Granulomatous hepatitis in three children due to cat-scratch disease without peripheral adenopathy: an unrecognized cause of fever of unknown origin. *Am J Dis Child* 1993; 147: 949-953.
12. Florin TA, Zaoukis TE, Zaoutis LB. Beyond Cat-Scratch Disease: widening spectrum of *Bartonella henselae* infection. *Pediatrics* 2008; 121: e1413-e1425.
13. Hadfield TL, Malatay RH, Van Dellen A, Wear DJ, Margileth AM. Electron microscopy of the bacilli causing cat-scratch disease. *J Infect Dis* 1985; 152: 643-645.
14. Margileth AM. Recent advances in diagnosis and treatment of cat-scratch disease. *Curr Infect Dis Rep* 2000; 2: 141-146.
15. Bass JW, Freitas BC, Freitas AD, et al. Prospective randomized double-blind placebo-controlled evaluation of azithromycin for treatment of cat-scratch disease. *Pediatr Infect Dis J* 1998; 17: 447- 452.
16. Santos R, Cardoso O, Rodrigues P, et al. Bacillary angiomatosis by *Bartonella quintana* in an HIV-infected patient. *J Am Acad Dermatol* 2000; 42: 299- 301.
17. David de Moraes JA, Bacellar F, Filipe A. Doença da arranhadura do gato com compromisso ósseo em indivíduo imunocompetente: uma forma rara de evolução. *Revista Portuguesa Doenças Infecciosas* 1997; 20: 48-53.
18. Cordero A, Escoto V, Lopes L. Endocardite por *Bartonella*: um caso de endocardite com culturas negativas. *Revista da Sociedade Portuguesa de Medicina Interna* 2008; 15 (3): 186 - 191.

Acknowledgments

The authors wish to thank to Dr Alfredo Fachada and Dr^a Sara Barbosa, veterinarians at the Clínica Veterinária Dr. Alberto Fachada – Estoril – Portugal, for their advisement on the *B. henselae* infection in cats, and for the collection of the blood of the kitten and also to Dr. Natacha Milhano for revising the English of the manuscript.