

Mucopolipidosis Type II and Type III: Nine cases from one Indian centre

Bhat M^{1,2*}, Sanjeeva GN², Maganti M², Devaiah S¹, Silji G¹, Undamatla J⁴, Coutinho F³, Alves S³

(1) Centre for Human Genetics, Bangalore, India, (2) Indira Gandhi Institute of Child Health, Bangalore, (3) Human Genetics Department, National Health Institute Dr. Ricardo Jorge, Porto, Portugal, (4) Sandor Life Sciences Pvt. Ltd., Hyderabad

*Email: bhat.meena@gmail.com

Introduction

- Mucopolipidosis II (MIM 252500) also known as I cell disease and MLIIA (MIM 252600) are rare lysosomal storage disorders caused by absent or diminished GlcNAc-phosphotransferase activity respectively. The resulting defective mannose phosphorylation affects transport of lysosomal hydrolases into the lysosome. Severe mutations in both alleles of *GNPTAB* encoding α and β subunits of GlcNAc-phosphotransferase result in MLI and MLIIA and heterozygous missense mutations are associated with familial persistent stuttering.
- Mucopolipidosis III gamma (MIM #252605) is a very rare variant affecting 1 in 1-4,00000 individuals. Mutations in *GNPTG* gene that cause mucopolipidosis III γ disrupt the tagging of digestive enzymes with mannose 6 phosphate (M6P), which prevents many enzymes from reaching the lysosomes.
- In this report, we describe clinical details from 9 cases from one Indian centre with mucopolipidosis II and III, including a sib pair with Type III γ with a novel homozygous mutation

Table 1: Clinical profile and laboratory investigations in 9 patients with Mucopolipidosis II and III

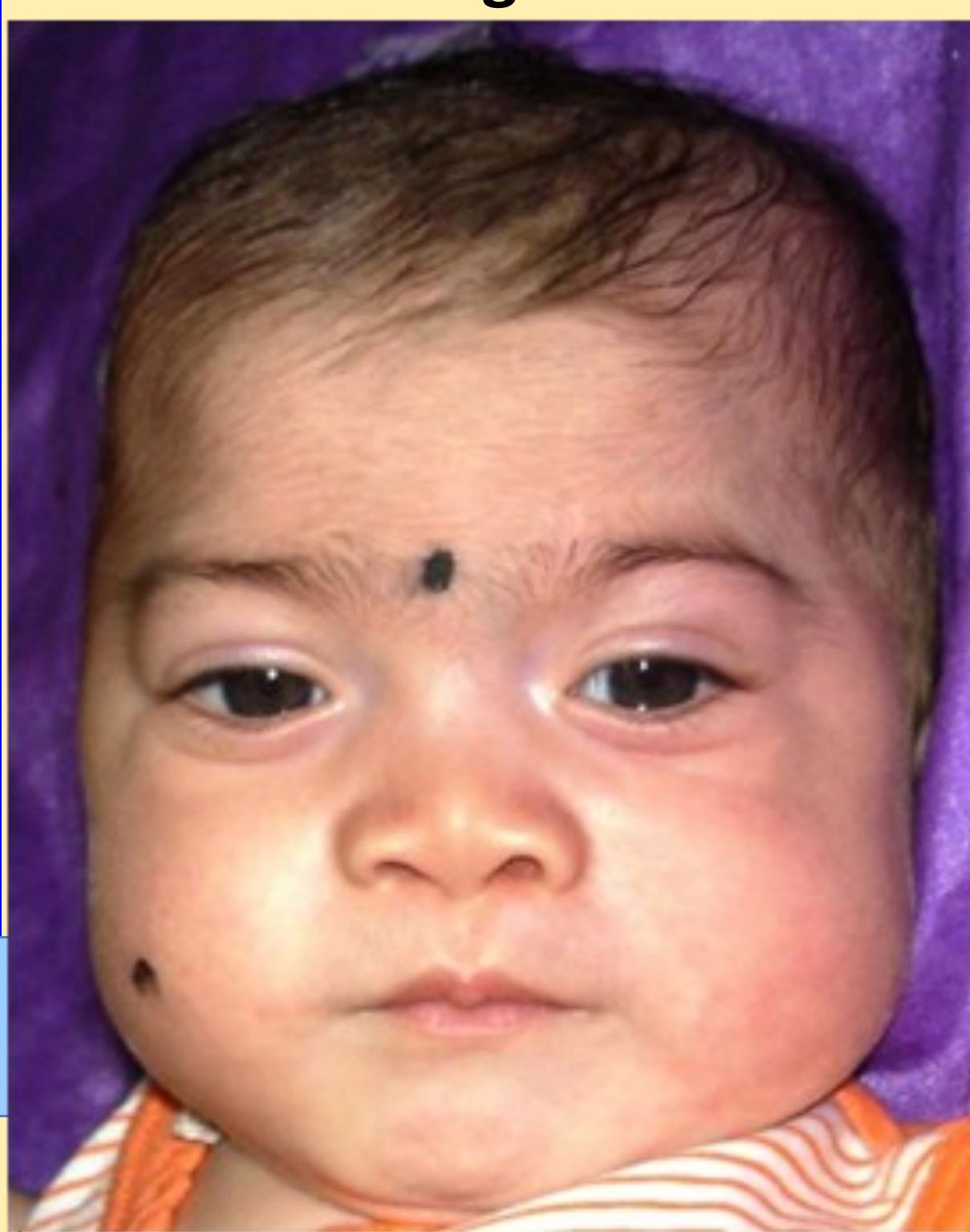Patient Name	1 Po	2 Ak	3 Tr	4 Ya	5 Sr	6 Na	7 Ch	8 Sri	9 Cha
Present age	15m	Died 2y11m	Died 1y11m	Died 4y9m	4 ½ y	3y2m	8 ½ y	5 ½ y	12y8m
Sex M/F	F	M	M	F	M	F	F	M	F
Age at diagnosis	9m	17m	16m	20m	3y	15m	7y	4y	5 ½ y
Parental consanguinity	Y/FC	Y/UN	N	N	Y, UN	Y/FC	Y/FC	Y/FC	Y/FC
Other affected family member	N	N	N	N	N	N	Y	Y	N
Birth weight (kgs)	2.25 C/S	2.19 C/S	2.2 C/S	2.45	<2	2.25	Home del	2.2	2
Coarse face	Y	Y	Y	Y	Y++	Y	Mild	Mild	Y
Wt at Diagnosis (kgs)	5	6.9	5.5	6.25	7.2	6.2	14.5	12.5	9
OFC (cms)	38	43.5	43.5	43	44.5	41	52	51	42.5
Craniosynostosis	N	N	N	Y	Y	N	Y	Y	Y
GDD	+	++	++	++ Mod	Mod	++	+	N	Mod
Eyes	Cloudy cornea Blepharitis	Cloudy cornea Ocular albinism	Cloudy cornea Fundus N	Mild V alt esotropia Fundus N	Cloudy cornea, temporal pallor	N	Early clouding	N	Mild clouding
Gum hypertrophy	Mild, no dentition	Y, no dentition	Y, no dentition	Y, No dentition till 4y	Y	Y, no dentition	Y	N	Y/ dental caries
Hirsutism	Y	Y	Y	Y	Y	Y	N	N	Mild
Respiratory problems	Stridor	Low O2 sats Rec LRI	Rec LRI	Rec LRI	Y, stridor LRI	Y	Y	N	N
CVS	PFO	N	Mod MR, AML prolapse	N 22m	MR+	Cardiac murmur	MR+	N	MR ++, AR
Hands	Clawed NCV N	Clawed NCV N	Clawed, bi-lateral SPC	Clawed No CTS	Clawed	Clawed	+++ CTS	+++ CTS	+++ from age 8y CTS
USG abdomen	N	N	N	N	N	N	N	N	Mild hepatomegaly
Skeletal survey	Typical	Typical	Typical	Mild 6m	Typical	Typical	Mod	Mod	Typical, osteoporosis
MRI brain	Microcephaly, N brain	No	Dilated lat ventricles	CT N	No	No	No	No	Craniosynostosis
Plasma Enzyme estimation									Not done
Alpha mannosidase	100X	40X	10X	40X	40X	44X	4X		4X
Alpha Fucosidase	10X	3.4X	96X	10X	5X	5X	3X		9X
Beta hexosaminidase Total	5X	3X	9X	6X	5X	4X	3X		11X
Others	OCT N	Died 2y11m Resp inf	5m: R inguinal hernia repair	R inguinal hernia	Lost FU Bilat inguinal herniae	Lost to FU	Sx for CTS	Sx for CTS	Sx for CTS Papules on lip mucosa
Mutation studies	c.3503_3504delTC (exon 19)	c.3335+1G>A hom, Ex 17	Declined test	Compd hetero. Ex 17 & Ex19	Not done	c.3503_3504delTC (exon 19)	c.512insG TGG (exon 7); p.H172WfsX28	c.512insG TGG (exon 7)	Awaited

FC: first cousin, UN: uncle niece, MR: mitral regurgitation, CTS: carpal tunnel syndrome, LRI: lower respiratory infection, OCT: optical coherence tomography

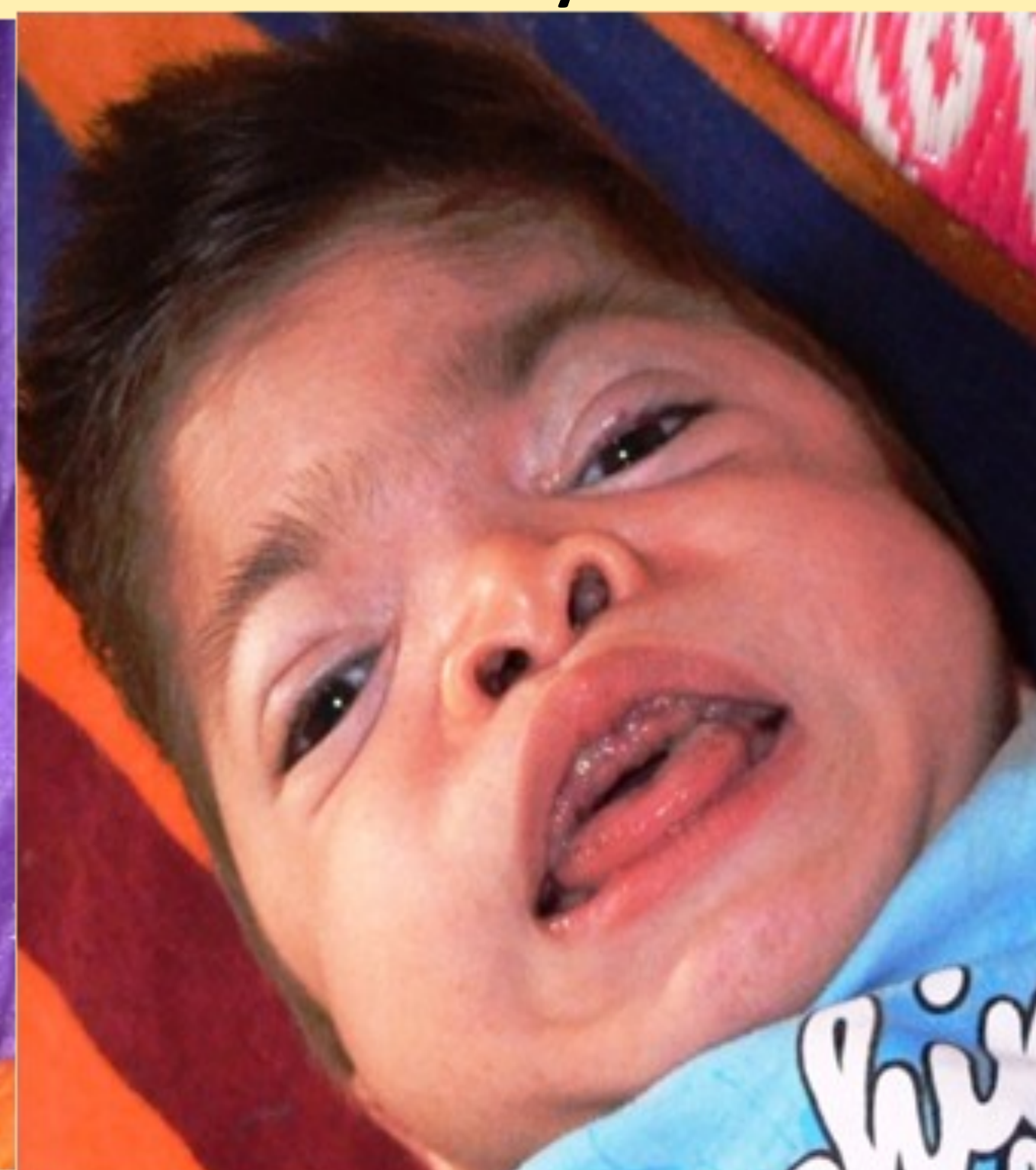Discussion

- Dysmorphic features, radiological and biochemical studies and mutation spectrum in nine cases (5 females and 4males) of MLI and III from one centre studied over a 6yr period are described here. Parental consanguinity was present in 6/8 (75%) families and two affected sibs were from one family. Age at diagnosis ranged from 5m to 5½ y. Perinatal skeletal abnormalities were described in two.
- Birth weight at term was < 2.5kgs in all. Growth was below the 3rd centile for all parameters with negligible increase beyond 2yrs age. Global developmental delay was seen in all with major motor and milder intellectual disabilities. Respiratory problems were present in 7/9 ranging from snoring, stridor and recurrent infections to progressive respiratory failure and three died of severe respiratory failure aged between 2y and 4y9m.
- Facial features present universally included coarse face, periorbital fullness, epicanthic folds, flat nasal bridge, triangular nasal tip, full lips, delayed or abnormal dentition and gingival hypertrophy. Progressive clawing of hands with restricted movements was seen in all nine. Three older children (6½ y, 8y and 12y8m) had a milder phenotype and all of these had craniosynostosis and bilateral carpal tunnel syndrome.
- Inguinal herniae, light coloured hair and irides and multiple mongoloid patches were seen in two patients each. One had persistent papular lesions on lip mucosa, not previously described.
- Full skeletal survey was done in all with typical dysostosis multiplex and osteopenia.
- Plasma enzymes (α Mannosidase, α Fucosidase and β Hexosaminidase) were elevated 3 to 40 fold in all tested.
- Echocardiography was abnormal in 6/8 with mitral regurgitation being the commonest defect.
- Corneal clouding was seen in 6/9 with ocular albinism (1), temporal pallor (1) and normal fundus in 7/9.
- Abnormal neuro-imaging was noted in 2/5 cases.
- Results of *GNPTAB* and *GNPTG* gene sequencing are available in six cases. Recurrent common mutations in Exons 17 and 19 of *GNPTAB* gene were noted in cases 1, 2, 4 and 6 (Table 1). A novel homozygous insertion was seen in Exon 7 of *GNPTG* gene in cases 7 and 8 (both sibs). Functional studies to further delineate this novel mutation have been planned.

Case 2: Age- 3m



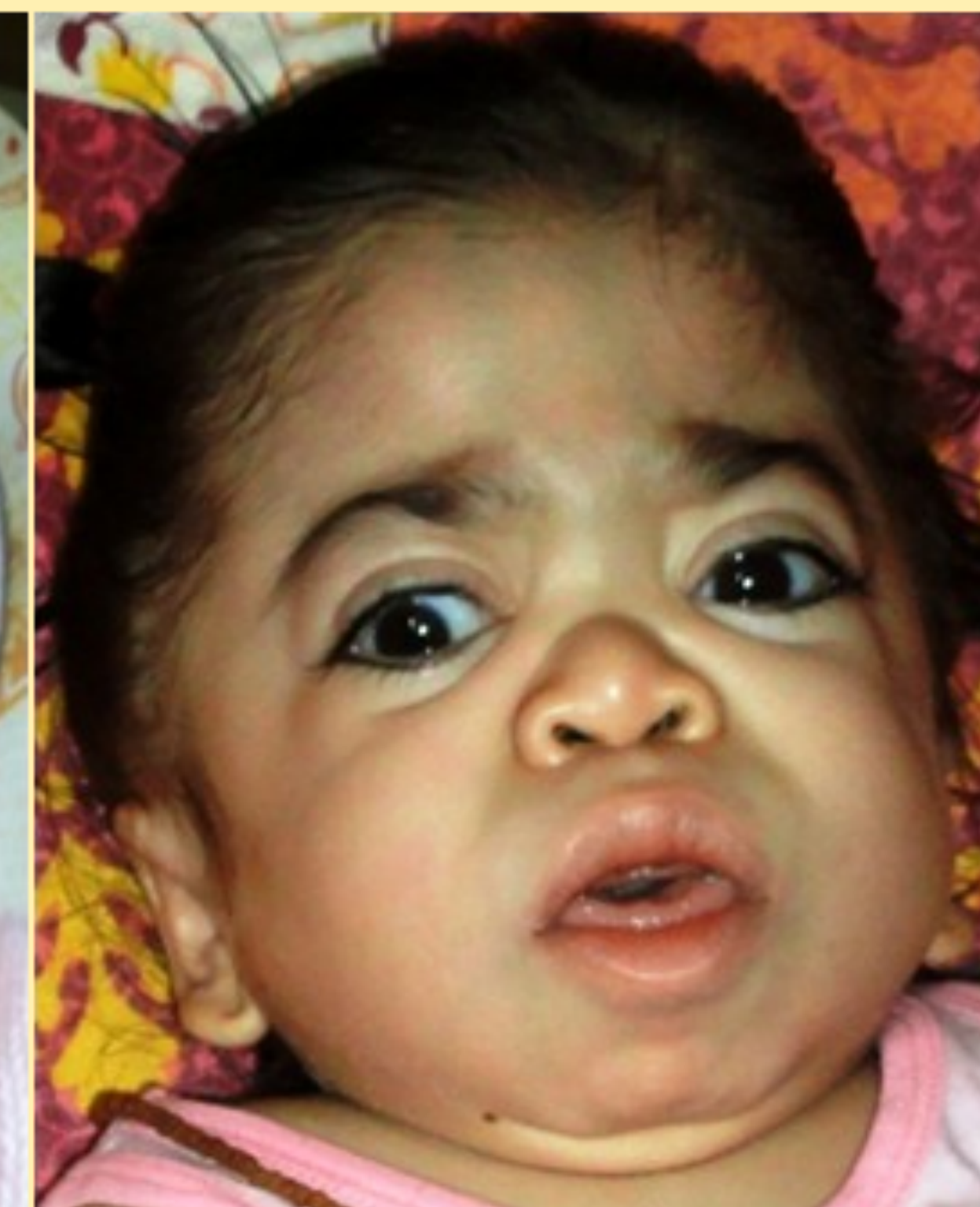2y6m



Case 4: Age - 7m



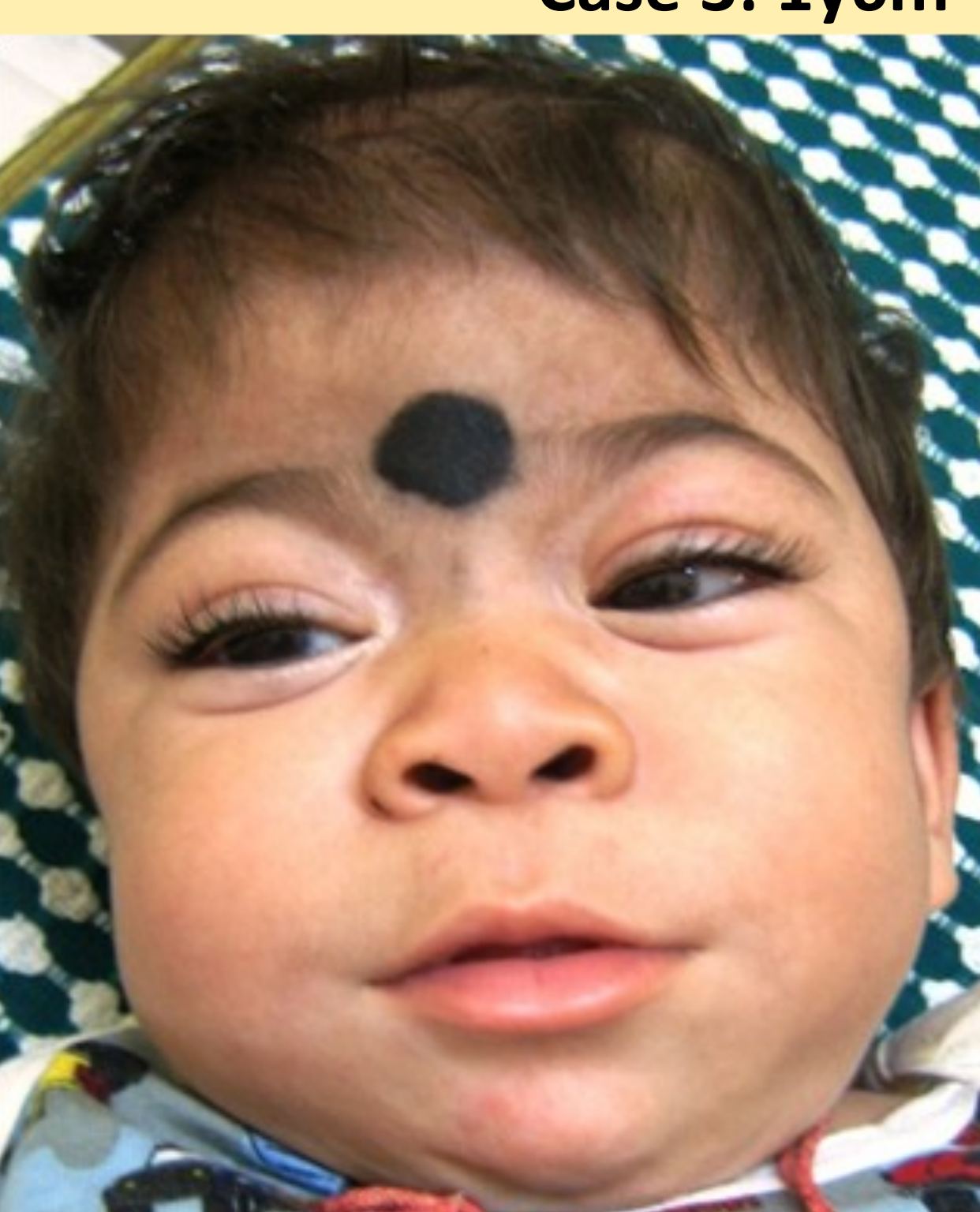4y



Case 6: 3y



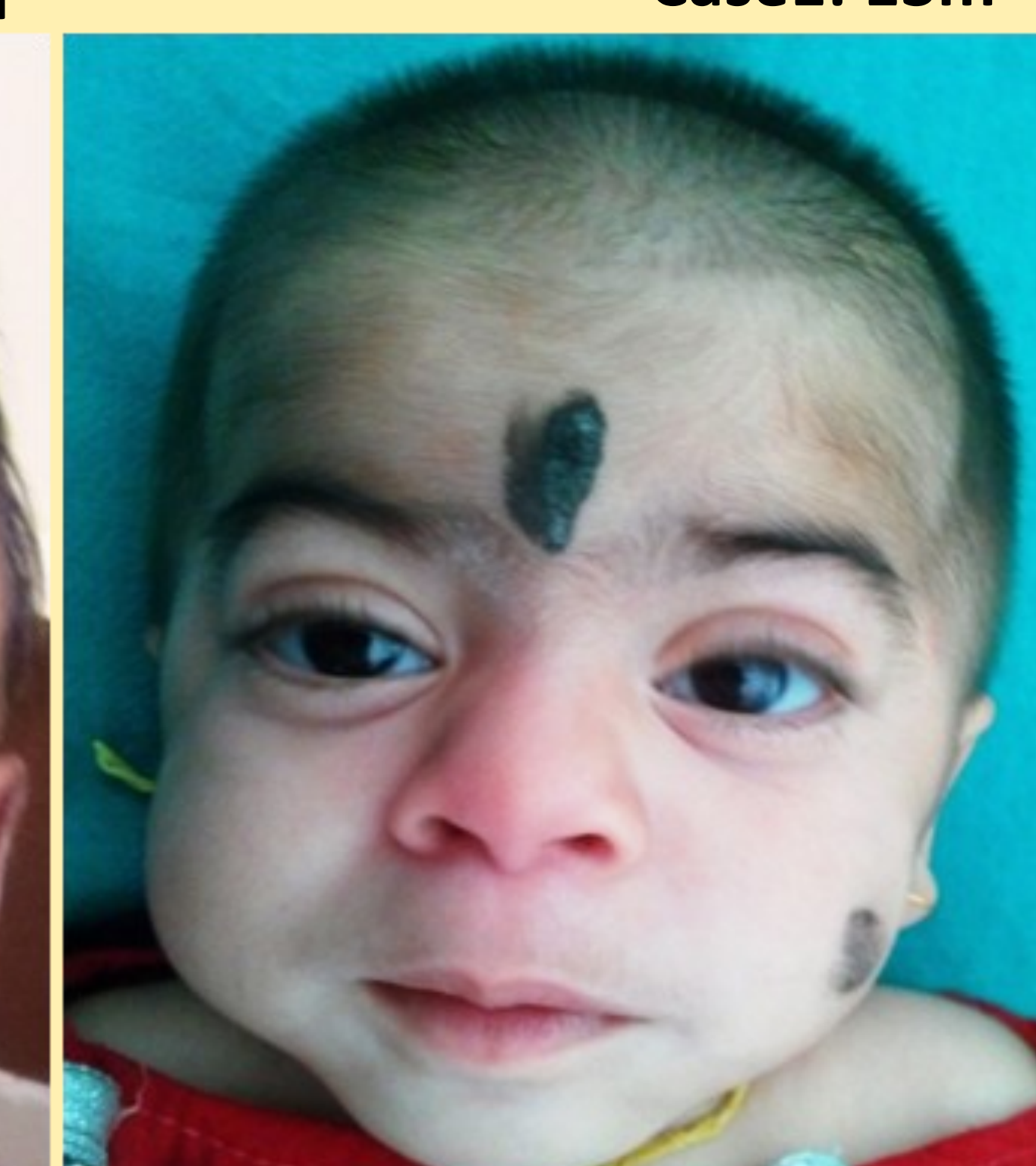Case 3: 1y6m



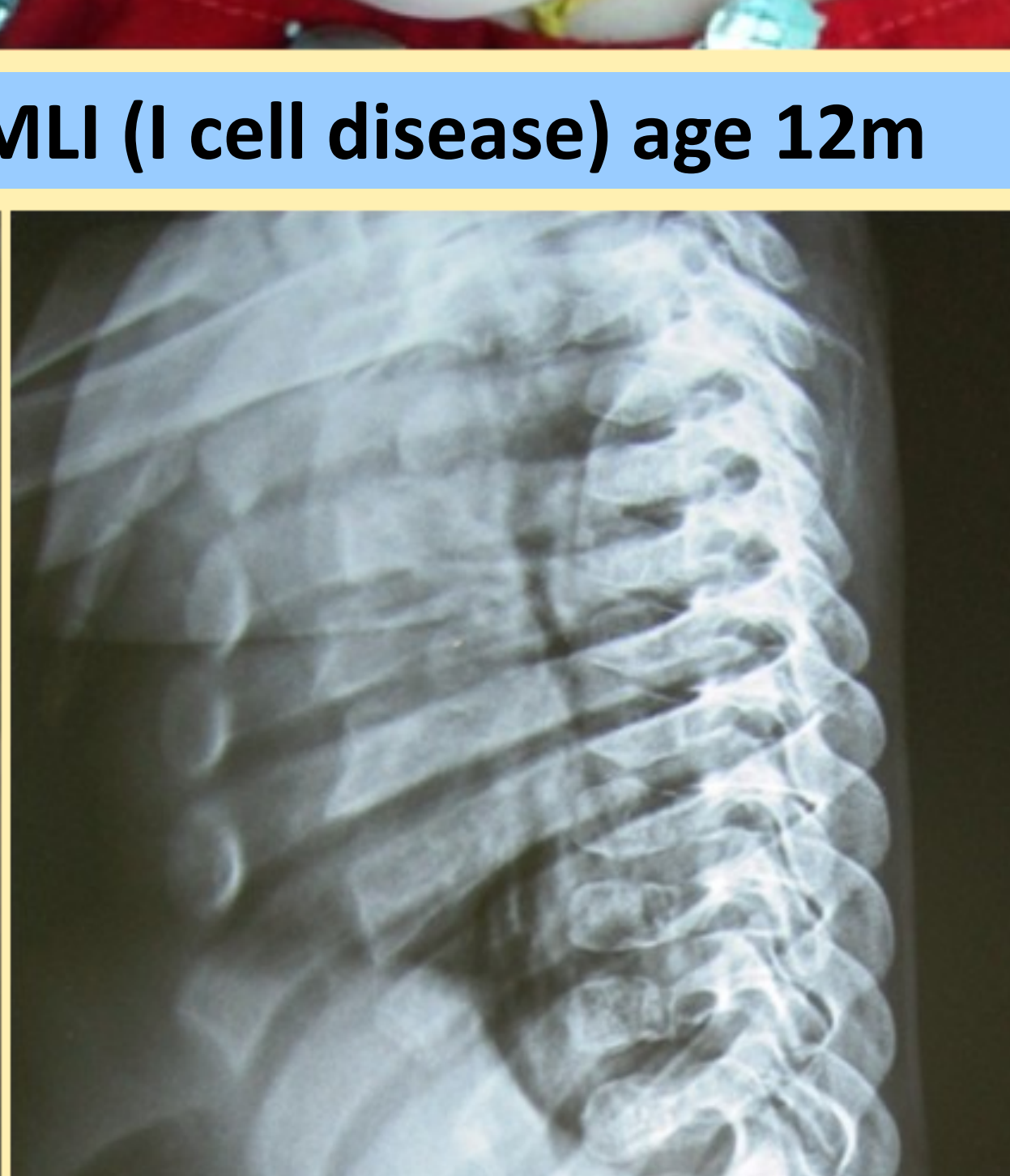
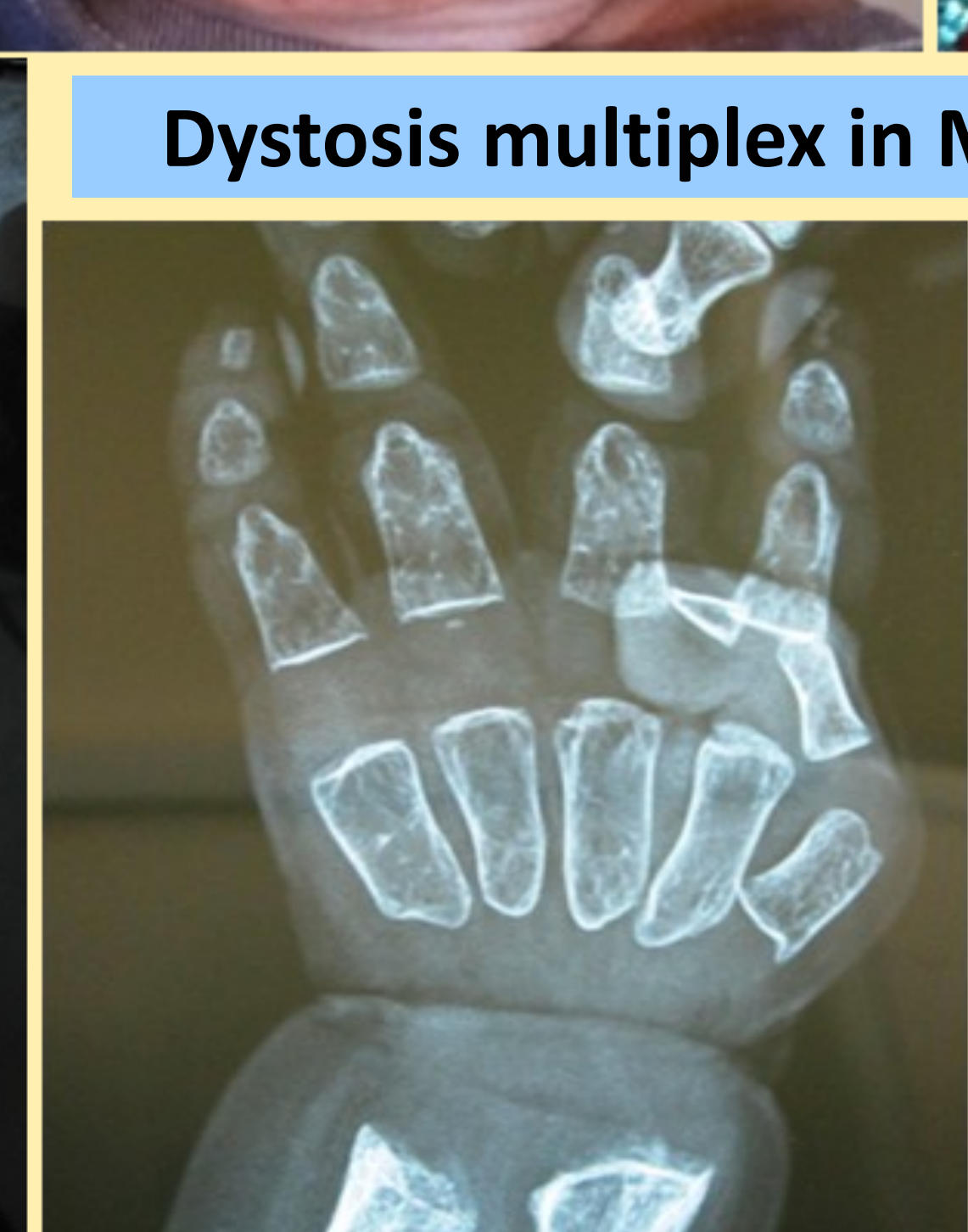
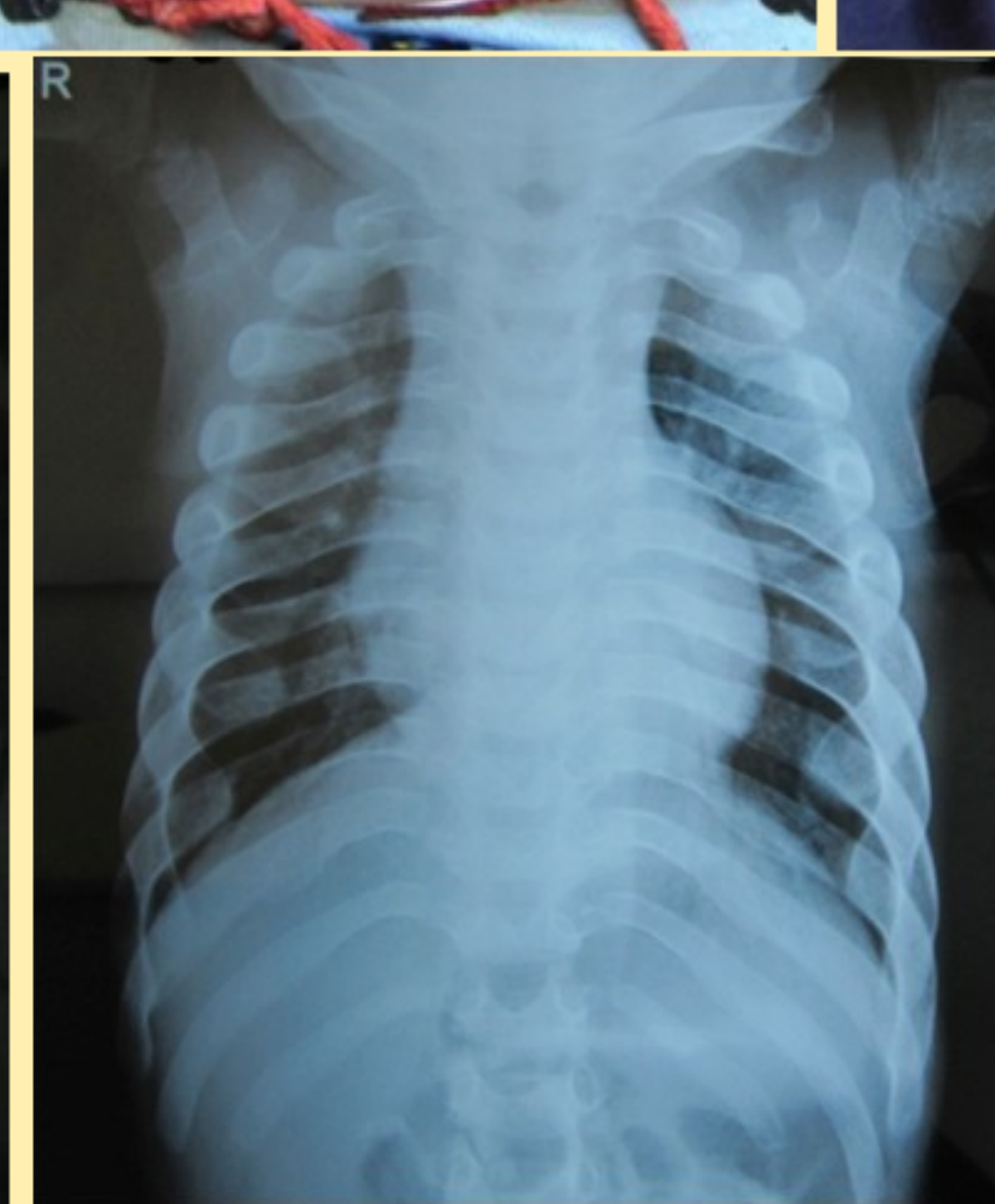
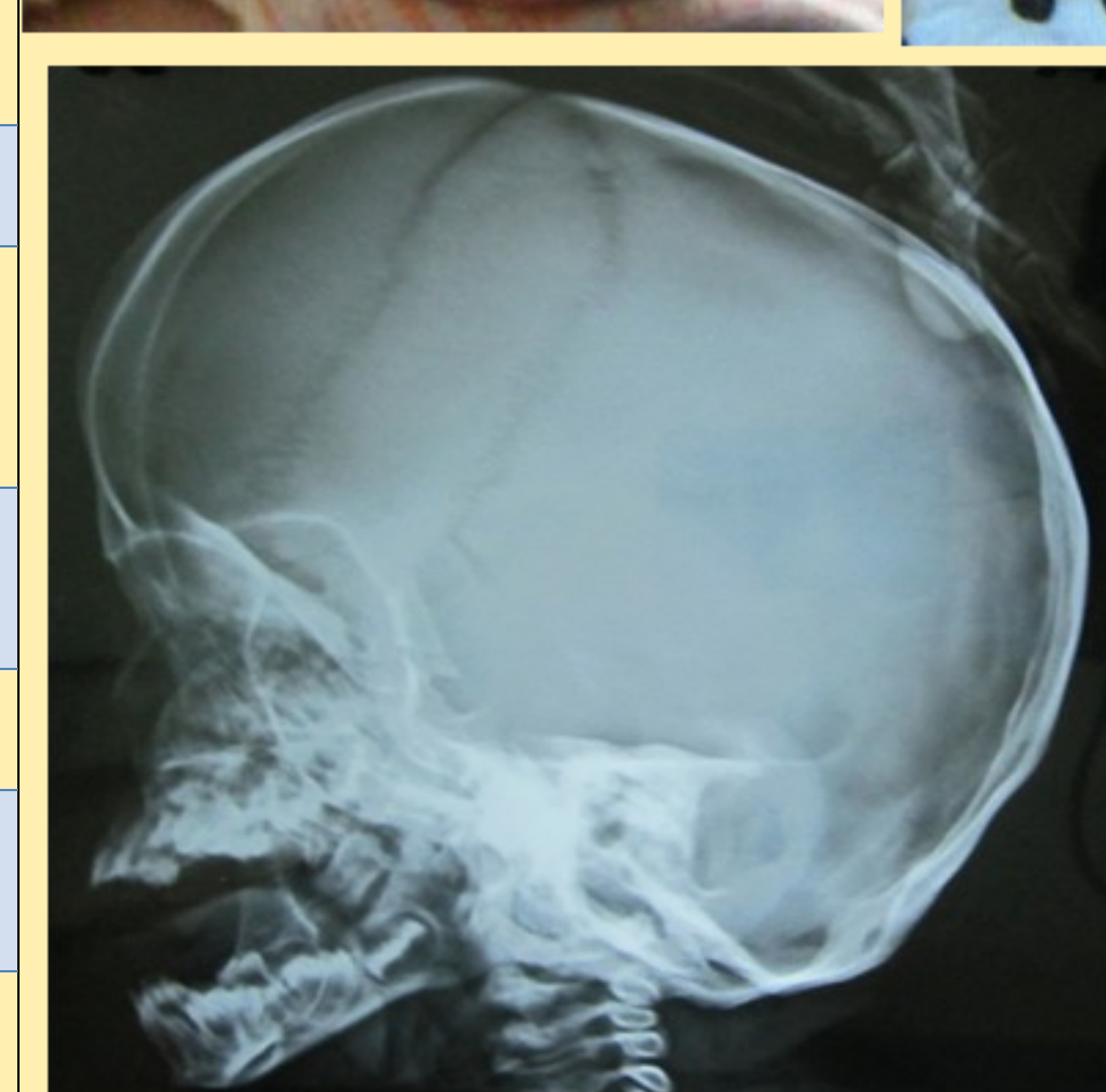Case 5: 3y4m



Case 1: 13m



Dystosis multiplex in MLI (I cell disease) age 12m



Radiology Description

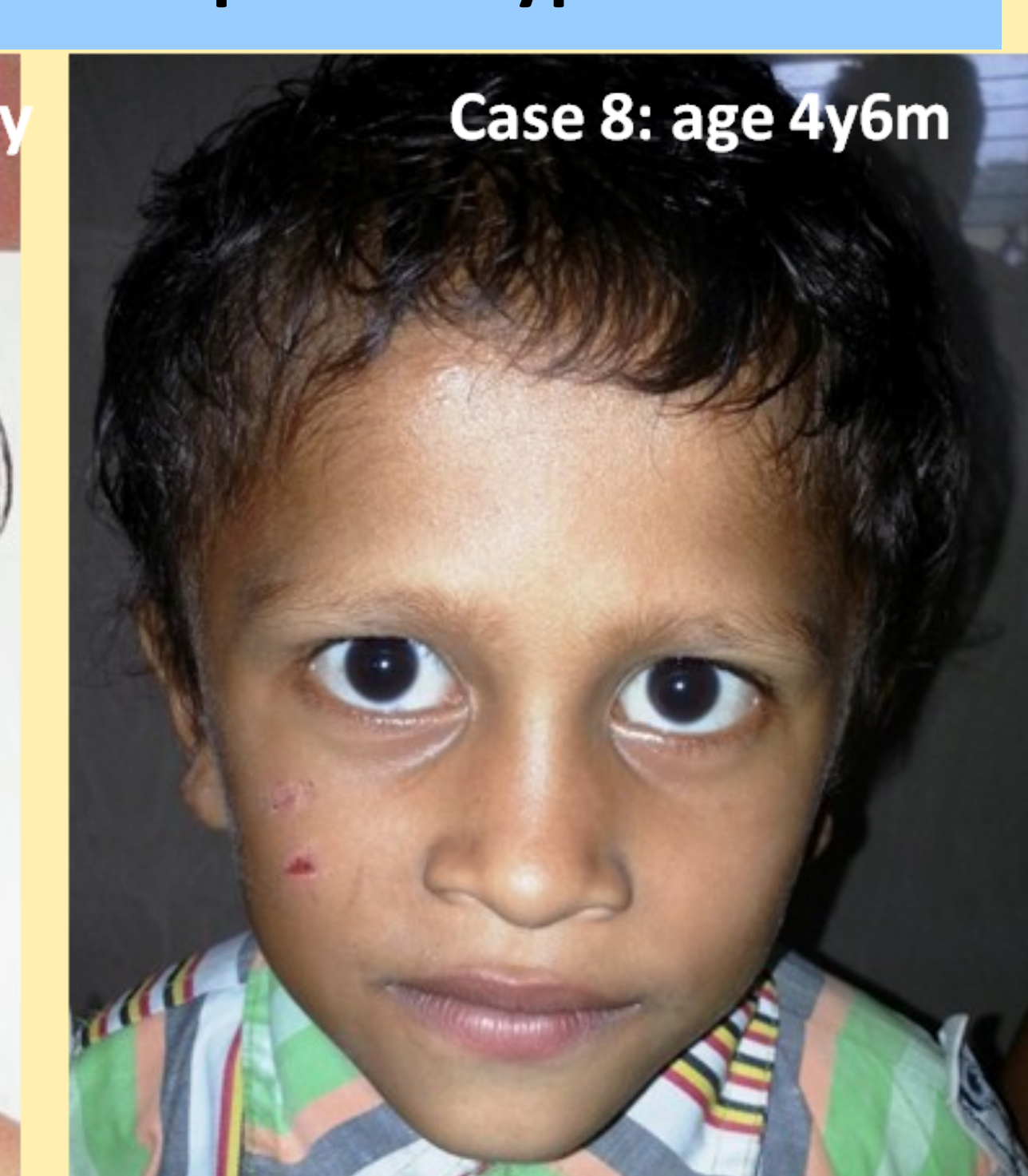- Skull that is relatively normal; widened sella turcica.
- Ribs widened at the costochondral junctions and narrower in the dorsal juxta-vertebral parts.
- Hand X-ray showing abducted thumb with diaphyseal widening and expansion of tubular bones. Osteopenia and bullet shaped metacarpals and phalanges. Delayed epiphyseal ossification.
- Rounded vertebral bodies with shortened antero-posterior diameter and antero-superior hypoplasia, mainly in the lower thoraco-lumbar vertebrae.
- Pelvic dysplasia with narrow basilar portions of the ilia and relatively long pubic and ischial bones, slanting acetabular roofs with coxa valga.

Type III γ

Face in Mucopolipidosis Type III



Case 7: age 8y



Case 8: age 4y6m



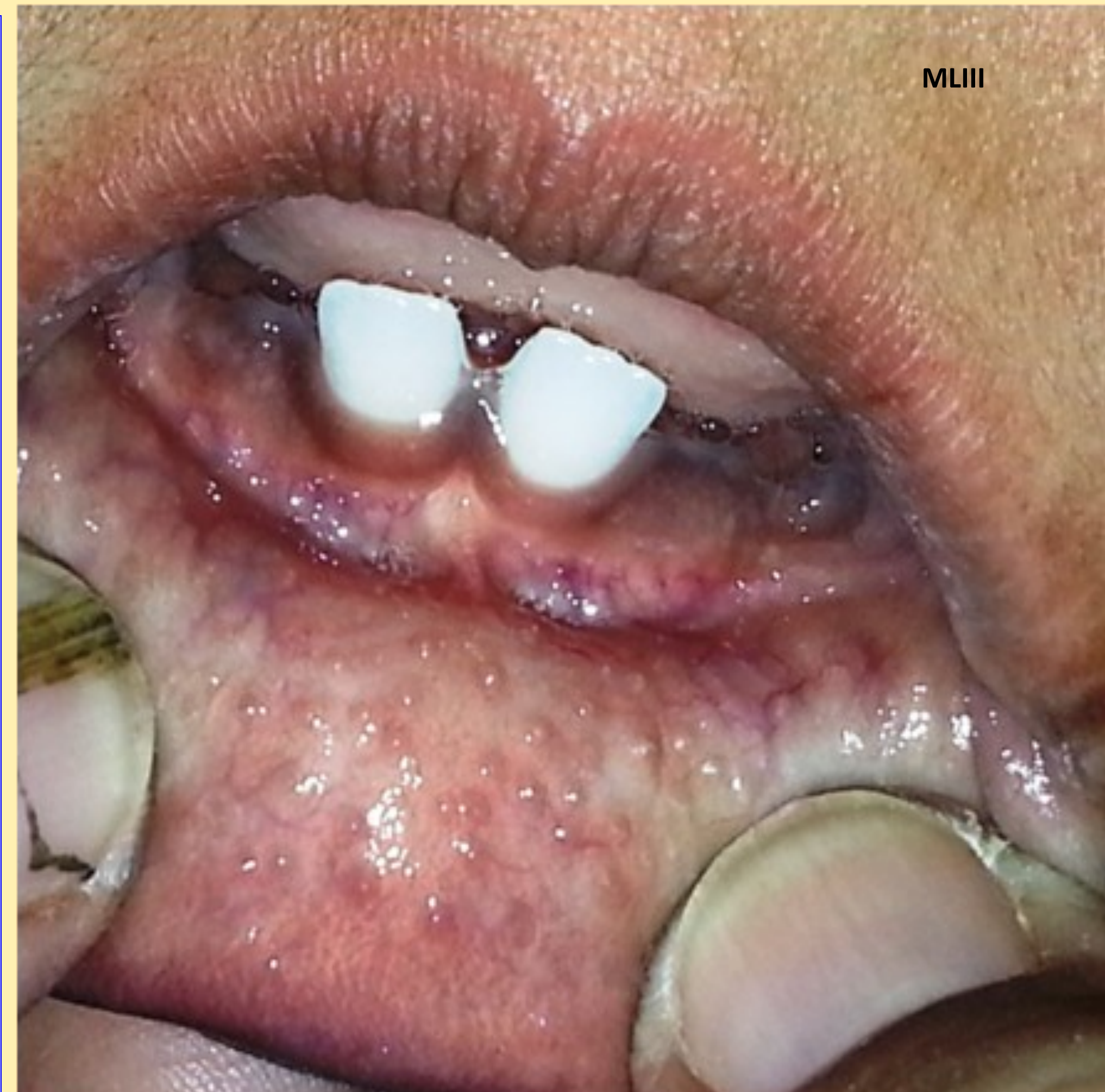Case 9: age 10y



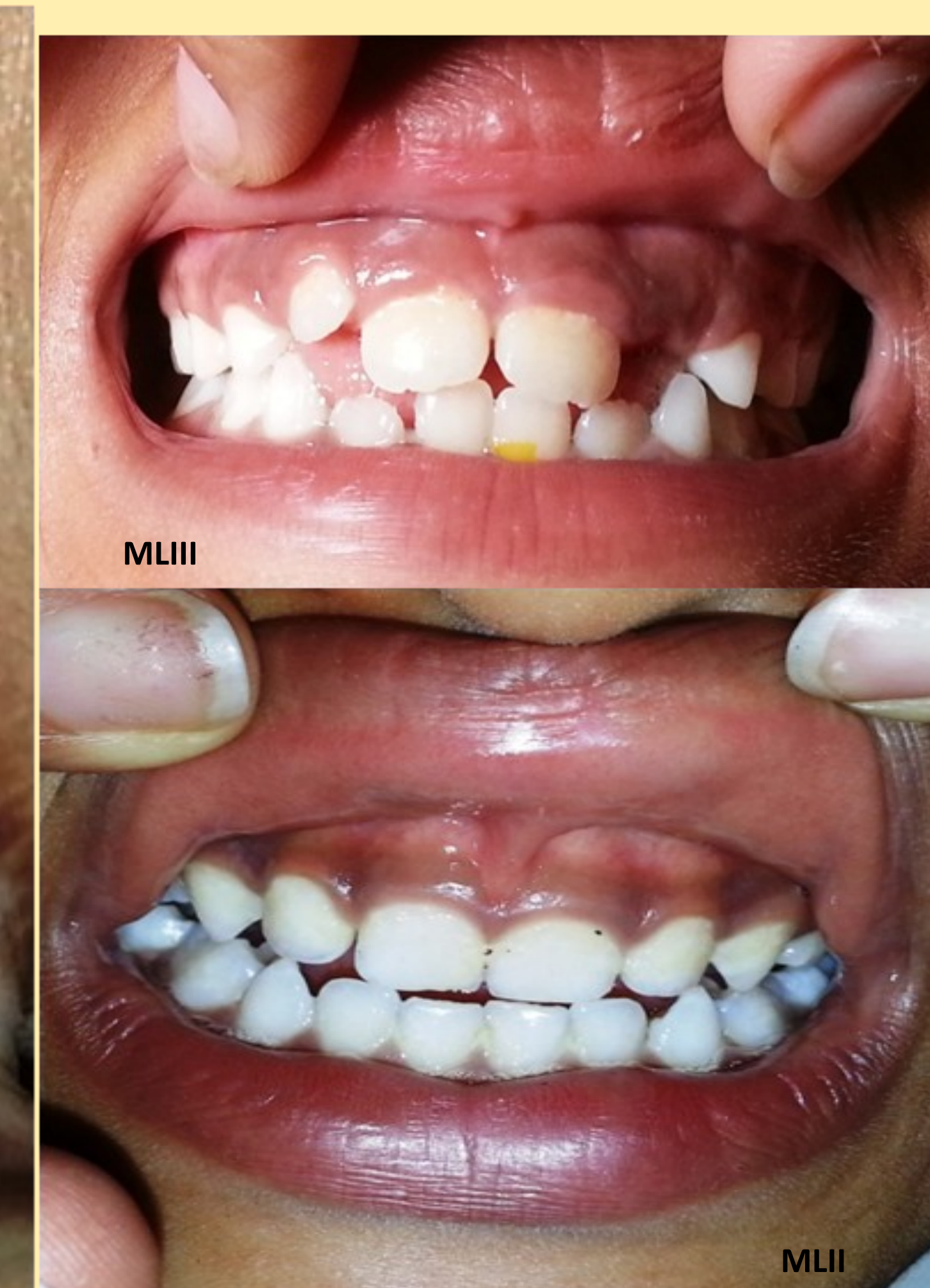13y6m

Sib pair with novel homozygous mutation c.512insGTGG (exon 7); p.H172WfsX28

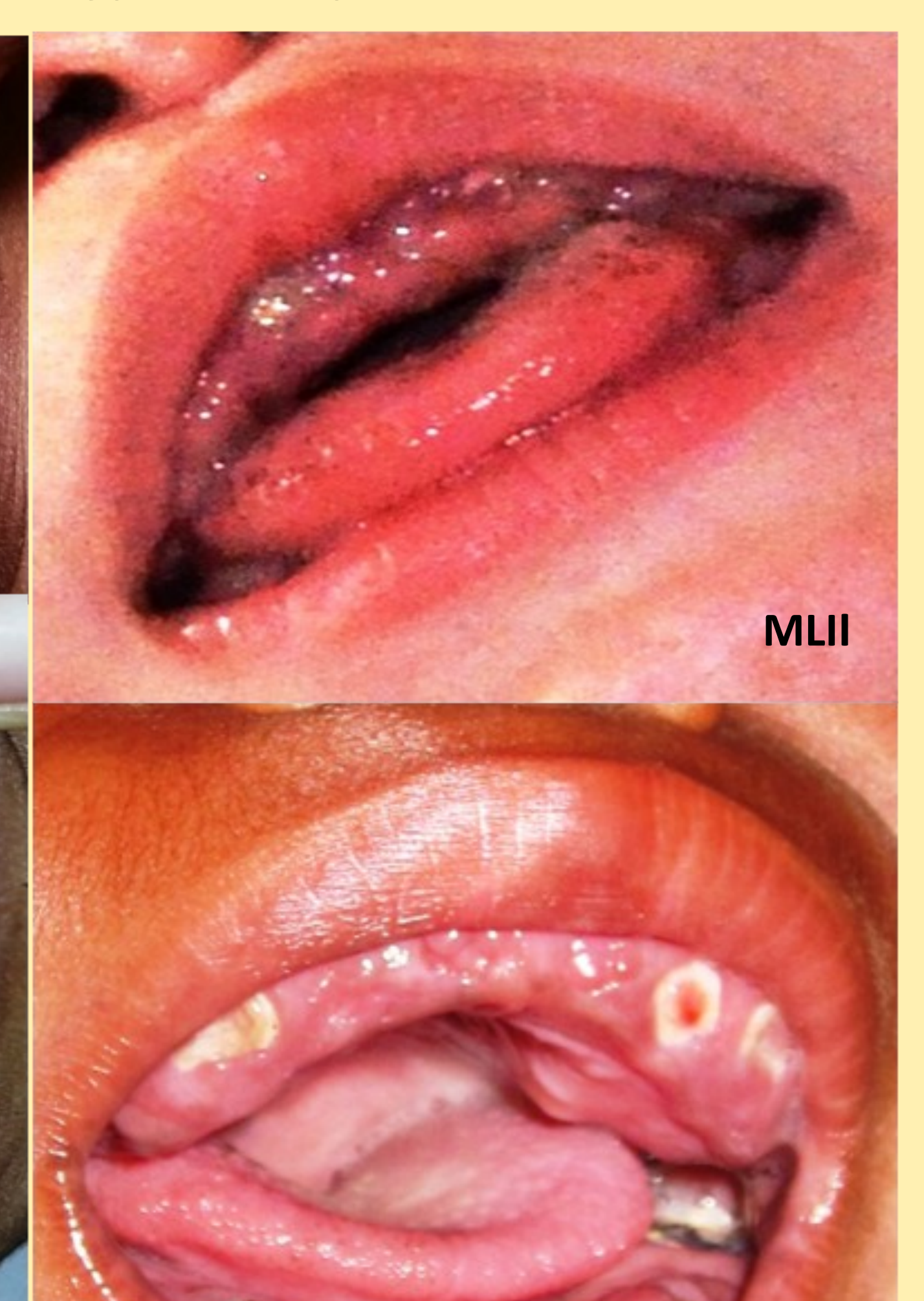Type III α/β



Above image shows papillary lesions on mucosa



Dentition: gum hypertrophy and dental caries in MLI, near normal in MLIII



MLII

References

- Mueller O T, Honey N K, Little L E, Miller A L, Shows T B. Mucopolipidosis II and III: the genetic relationships between two disorders of lysosomal enzyme biosynthesis. J. Clin. Invest. 72, 1983
- Canfield W M, Bao M, Pan J, et al., A. Mucopolipidosis II and mucopolipidosis IIIA are caused by mutations in the GlcNAc-phosphotransferase alpha/beta gene on chromosome 12p. (Abstract) Am. J. Hum. Genet. 63, 1998
- Tiede S., Storch S., Lubke T, et al., Mucopolipidosis II is caused by mutations in GNPTA encoding the alpha/beta GlcNAc-1-phosphotransferase. Nature Med. 11, 2005
- Encarnacao M, Lacerda L, Costa R, et al., Molecular analysis of the GNPTAB and GNPTG genes in 13 patients with mucopolipidosis type II or type III - identification of eight novel mutations. Clin. Genet. 76, 2009.
- Raas-Rothschild A, Cormier-Daire V, Bao M, et al., Molecular basis of variant pseudo-Hurler polydystrophy (mucopolipidosis IIIC). J. Clin. Invest. 105, 2000
- Coutinho M F, Encarnacao M, Gomes R, et al., Origin and spread of a common deletion causing mucopolipidosis type II: insights from patterns of haplotypic diversity. Clin. Genet. 80, 2011
- Changsoo Kang, Drayna D, A role for inherited metabolic deficits in persistent developmental stuttering. Mol Genet Metab. 107(3), 2012

